



MEDICOLEGAL INVESTIGATION
INTO THE DEATHS OF
SYMBIONESE LIBERATION ARMY MEMBERS
LOS ANGELES
(PART 1)



THOMAS T. NOGUCHI, M.D.
Chief Medical Examiner-Coroner
County of Los Angeles



COUNTY OF LOS ANGELES
DEPARTMENT OF CHIEF MEDICAL EXAMINER-CORONER

1104 NO. MISSION RD., LOS ANGELES, CALIFORNIA 90033

(213) 223-3231

THOMAS T. NOGUCHI, M.D.
CHIEF MEDICAL EXAMINER-CORONER

INTRODUCTION

Pursuant to the California Government Code, the Department of Chief Medical Examiner-Coroner has investigated the circumstances surrounding the deaths of six members of the Symbionese Liberation Army, who died during an encounter with the Los Angeles Police Department.

This report includes the at-scene investigation, Forensic Autopsy findings, and the Forensic Laboratory data.

Additional scientific investigations and laboratory testing are still being conducted in various phases: psychological autopsy, scanning electron microscopic examination and neutron activation analysis of physical evidence. The results will be reported in Part II.

The modes of death will not be determined until completion of the additional studies.

Thomas T. Noguchi, M.D.

COUNTY OF LOS ANGELES
DEPARTMENT OF CHIEF MEDICAL EXAMINER-CORONER
LOS ANGELES, CALIFORNIA 90033

TABLE OF CONTENTS

INTRODUCTION

| | |
|--|-----|
| General At-Scene Investigation | i |
| Position of Decedents At-Scene (Diagram) | ii |
| Personnel | iii |

NANCY LING PERRY

| | |
|--|----|
| Cause of Death | 1 |
| Anatomical Summary | 2 |
| Summary of Gunshot Wounds | 2 |
| Description of Gunshot Wounds | 5 |
| Microscopic Description of Gunshot Wounds | 8 |
| Postmortem Damage Due to Exploding Ammunition | 9 |
| General External Description | 10 |
| General Microscopic Description | 12 |
| Forensic Neuropathology Examination | 14 |
| Forensic Radiology Examination | 15 |
| Forensic Odontology Examination | 16 |
| Forensic Toxicology Examination | 17 |
| Forensic Biology Examination | 18 |
| Body Charts | 19 |
| Odontology Chart | 21 |
| Report of At-Scene and Follow-Up Investigation | 22 |

ANGELA ATWOOD

| | |
|-------------------------------------|----|
| Cause of Death | 23 |
| Anatomical Summary | 24 |
| General External Description | 24 |
| General Microscopic Description | 26 |
| Forensic Neuropathology Examination | 29 |
| Forensic Radiology Examination | 30 |
| Forensic Odontology Examination | 31 |
| Forensic Toxicology Examination | 31 |

| | |
|--|----|
| Forensic Biology Examination | 32 |
| Odontology Chart | 33 |
| Report of At-Scene and Follow-Up Investigation | 34 |

WILLIAM LAWTON WOLFE

| | |
|--|----|
| Cause of Death | 35 |
| Anatomical Summary | 36 |
| Description of Burns | 36 |
| Postmortem Damage from Exploding Ammunition | 36 |
| General External Description | 37 |
| General Microscopic Description | 39 |
| Forensic Neuropathology Examination | 42 |
| Forensic Radiology Examination | 43 |
| Forensic Odontology Examination | 44 |
| Forensic Toxicology Examination | 45 |
| Forensic Biology Examination | 46 |
| Body Charts | 47 |
| Odontology Chart | 49 |
| Report of At-Scene and Follow-Up Investigation | 50 |

DONALD DeFREEZE

| | |
|--|----|
| Cause of Death | 51 |
| Anatomical Summary | 52 |
| Summary of Gunshot Wounds | 52 |
| Description of Gunshot Wounds | 53 |
| Microscopic Description of Gunshot Wounds | 54 |
| General External Description | 55 |
| General Microscopic Description | 58 |
| Forensic Neuropathology Examination | 61 |
| Forensic Radiology Examination | 64 |
| Forensic Odontology Examination | 65 |
| Forensic Toxicology Examination | 66 |
| Forensic Biology Examination | 66 |
| Body Charts | 67 |
| Odontology Chart | 70 |
| Report of At-Scene and Follow-Up Investigation | 71 |

PATRICIA SOLTYSIK

| | |
|---|----|
| Cause of Death | 72 |
| Anatomical Summary | 73 |
| Summary of Gunshot Wounds | 73 |
| Description of Gunshot Wounds | 74 |
| Microscopic Description of Gunshot Wounds | 76 |

| | |
|--|----|
| Postmortem Damage from Exploding Ammunition | 76 |
| General External Description | 77 |
| General Microscopic Description | 79 |
| Forensic Neuropathology Examination | 81 |
| Forensic Radiology Examination | 83 |
| Forensic Odontology Examination | 84 |
| Forensic Toxicology Examination | 84 |
| Forensic Biology Examination | 85 |
| Body Charts | 86 |
| Odontology Chart | 88 |
| Report of At-Scene and Follow-Up Investigation | 89 |

CAMILLA HALL

| | |
|--|-----|
| Cause of Death | 90 |
| Anatomical Summary | 91 |
| Summary of Gunshot Wounds | 91 |
| Description of Gunshot Wounds | 92 |
| Microscopic Description of Gunshot Wounds | 92 |
| General External Description | 93 |
| General Microscopic Description | 95 |
| Forensic Neuropathology Examination | 96 |
| Forensic Radiology Examination | 97 |
| Forensic Odontology Examination | 98 |
| Forensic Toxicology Examination | 99 |
| Body Charts | 100 |
| Odontology Chart | 101 |
| Report of At-Scene and Follow-Up Investigation | 102 |

REPORT OF GENERAL AT-SCENE INVESTIGATION

At approximately 1930 hours on May 17, 1974, the Coroner was notified by the Los Angeles Police Department that an incident had occurred at 1466 East 54th Street, Los Angeles, and that there were two known, and possibly five, deceased persons at that location.

At 1955 hours, a Senior Investigator and an Investigator were dispatched to the location, arriving at 2015 hours. On arrival it was determined that the total known dead was five, consisting of three females and two males.

Information received from the investigating police officer indicated that the residence at 1466 East 54th Street was occupied by two females, their children, and male friends. The five decedents were reported to have arrived at the location between 0300 and 0400 hours on May 16, 1974, stating that their van had broken down, and requesting permission to spend the night. Permission was apparently given. Details of the happenings of May 16, 1974 were unknown at this time; however, it is presently believed that the five decedents may have held hostage the occupants of the house. It was reported that some of the decedents had left and returned to the residence several times during the day, and also that police officers had located and recognized the decedents' van, parked near 1466 East 54th Street, which had been sought because of involvement in another incident. It was reported that at approximately 1755 hours on May 17, 1974, the area had been cordoned off by police officers, and by use of the bullhorn the occupants had been ordered to leave the residence; and that at approximately 1900 hours, following many gunshots, the residence caught fire, the cause of which is unknown at this time.

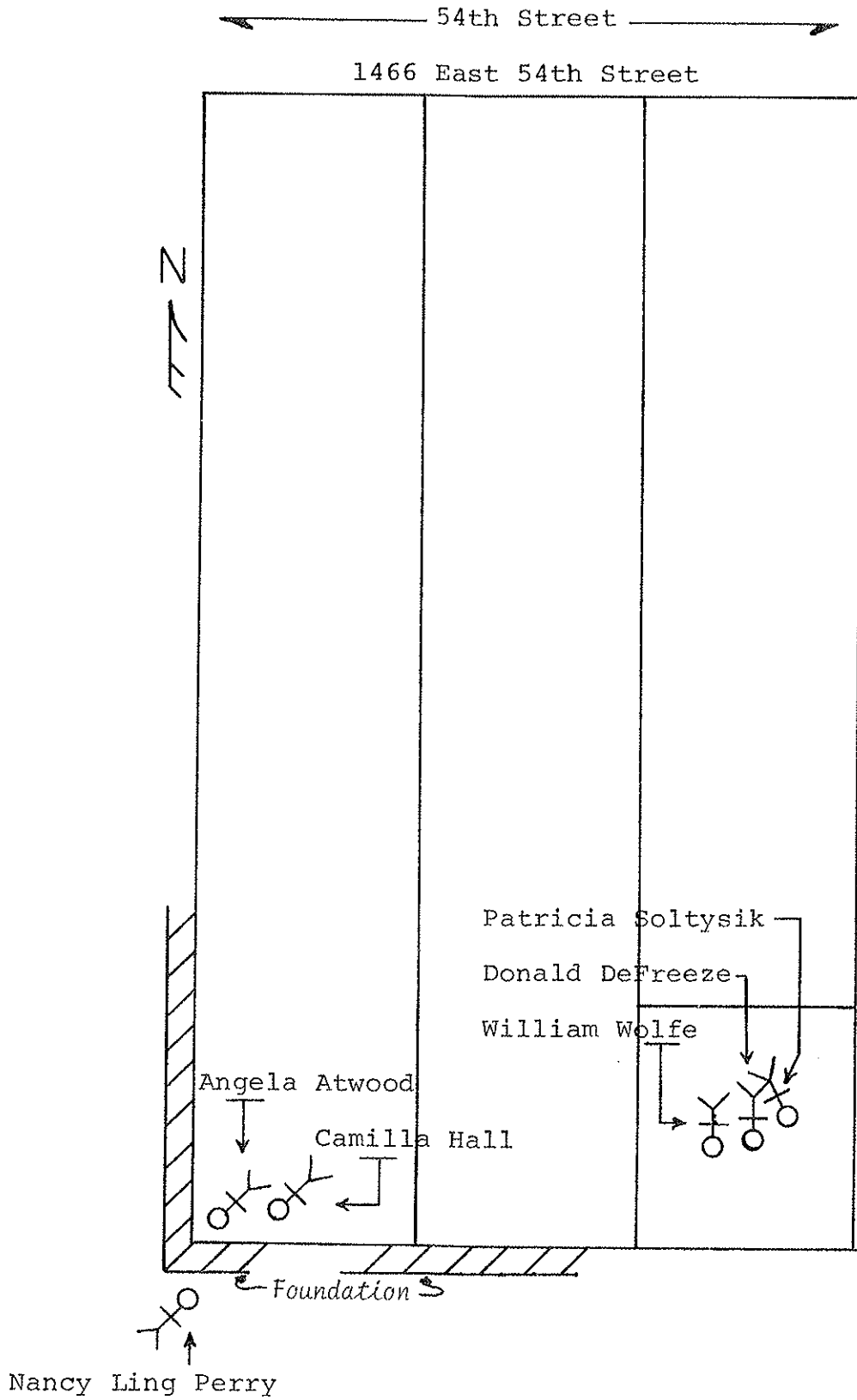
The Los Angeles Fire Department was summoned to the location. Task Forces 10 and 26, and Engine Companies 21 and 22 responded. The five decedents were pronounced dead by the Los Angeles Fire Department personnel at 1930 hours.

The understanding, at present time, is that all hostages had managed to escape, but the circumstances of escape or release are currently under investigation.

Numerous rounds of various caliber ammunition were noted at the location, some live and some spent. The investigating police officers stated that several bombs were also recovered, and that possibly more bombs and a number of weapons were still among the ashes at the location.

Photographs were taken at-scene before removal of the bodies to the Forensic Science Center.

POSITION OF DECEDENTS AT-SCENE



PERSONNEL

County Official in Charge of Medicolegal Investigations:

Thomas T. Noguchi, M.D.
Chief Medical Examiner-Coroner
County of Los Angeles

Aide in Charge of Interagency Relations:

Donald A. Drynan
Assistant Coroner

Forensic Pathologists:

Thomas T. Noguchi, M.D.
Chief Medical Examiner-Coroner

Dean V. Wiseley, M.D.
Chief, Forensic Medicine Division

Manuel R. Breton, M.D.
Deputy Medical Examiner

Gaston Herrera, M.D.
Deputy Medical Examiner

Richard A. Pihl, M.D.
Deputy Medical Examiner

Victor J. Rosen, M.D.
Deputy Medical Examiner

Forensic Neuropathologist:

Abraham T. Lu, M.D.
Deputy Medical Examiner

Forensic Radiologist:

Isaac Sanders, M.D.
Deputy Medical Examiner

Forensic Odontologists:

Gerald L. Vale, D.D.S., J.D.
Chief, Forensic Dentistry Branch

Phillip E. Peck, D.D.S.
Deputy, Forensic Dentistry Branch

Forensic Toxicologists:

George R. Nakamura, Ph.D.
Chief, Forensic Toxicology and Biology Division
and Forensic Toxicology Personnel

Investigations Division:

Ralph M. Bailey,
Chief, Investigations Division

At-Scene and Follow-Up Investigation:

C. Robert Dambacher
Assistant Chief, Investigations Division

A. Charles Lien
Coroner's Senior Investigator

Stanley C. Stratton
Coroner's Investigator

Forensic Photography and Radiography:

William H. Lystrup
Head, Forensic Services

James A. Njavro
Medical Photographer

Other individuals were present from time to time during the autopsy for various purposes. The names of these authorized persons appear on rosters maintained by the department and other agencies also bearing responsibility for the security of the autopsy room.

COUNTY OF LOS ANGELES
DEPARTMENT OF CHIEF MEDICAL EXAMINER-CORONER
LOS ANGELES, CALIFORNIA 90033

JANE DOE NO. 1, aka NANCY LING PERRY

Case No. 74-6761

This is to certify that the autopsy on the body of Nancy Ling Perry was performed at The Forensic Science Center, Los Angeles, by the staff of the Department of Chief Medical Examiner-Coroner, on May 18, 1974.

CAUSE OF DEATH: MULTIPLE GUNSHOT WOUNDS

The detailed medical findings, opinions and conclusions required by Section 27491 of the Government Code of California are attached.

Thomas T. Noguchi, M.D.
Chief Medical Examiner-Coroner

ANATOMICAL SUMMARY

GUNSHOT WOUNDS

1. Gunshot wound of back, perforating right lung, liver and right breast, fatal.
2. Gunshot wound of back, perforating spine and spinal cord, fatal.
3. Gunshot wound of right hip, involving pelvis, vulva and left buttock, potentially fatal.
4. Gunshot wound of right thigh, fracturing femur, non-fatal.
5. Gunshot wound of right thigh, perforating skin and subcutaneous tissue, non-fatal.
6. Gunshot wound of left thigh, penetrating soft tissue, non-fatal.
7. Gunshot wound of right upper arm, perforating soft tissue, non-fatal.

OTHER PERTINENT FINDINGS

1. Retropleural hemorrhage and hemothorax, right.
2. Cutaneous thermal burns.
3. Postmortem charring of body.
4. Postmortem damage from exploding ammunition.

SUMMARY OF GUNSHOT WOUNDS

Gunshot Wound No. 1, Back, Fatal
(Perforating Right Lung, Liver and Right Breast)

Entry: Right posterolateral back area.

Direction: Slightly right to left, posterior to anterior, inferior to superior.

Course: Posterior muscles and posterior ribs, bullet splitting into major fragments (a) and (b);

Fragment (a) through lateral muscles and right breast;

Fragment (b) through right lung;

Other small fragments passed into right lung and through liver.

Exit: Fragment (a) through right breast;

Fragment (b) none.

JANE DOE NO. 1, aka NANCY LING PERRY

Projectile Recovery and Identification: Fragment (a): small fragment of copper jacket material from right breast;

Fragment (b): .223 caliber jacket and partial core.

Gunshot Wound No. 2, Back, Upper Right, Fatal
(Perforating spine and spinal cord)

Entry: Right upper back.

Direction: Generally right to left, posterior to anterior, fragmenting both inferiorly and superiorly.

Course: Into scapula, bullet splitting into major fragments (a) and (b);

Fragment (a) remaining in muscles of back;

Fragment (b) through thoracic vertebra and spinal cord to left supraclavicular area.

Exit: Fragment (a) Portion of this fragment exited right mid back;

Fragment (b) Portion of this fragment exited the left supraclavicular area.

Projectile Recovery and Identification: Fragment (a): portion of jacket material;

Fragment (b): .223 caliber jacket and core material.

Gunshot Wound No. 3, Right Hip, Potentially Fatal
(Involving bony pelvis, vulva and left buttock)

Entry: Right hip, lateral aspect.

Direction: Right to left, very slightly anterior to posterior, slightly inferior to superior.

Course: Right upper thigh, pelvis, through vulva and left buttock.

JANE DOE NO. 1, aka NANCY LING PERRY

Exit: Outer aspect of left buttock.
Projectile Recovery and Identification: Small metallic fragments from wound track. (Unidentified lead fragment)

Gunshot Wound No. 4, Right Thigh, Non-Fatal
(Fracturing femur)

Entry: Posterolateral aspect area of right lower thigh.
Direction: Right to left, slightly posterior to anterior, slightly inferior to superior.
Course: Subcutaneous and muscular tissue through right femur.
Exit: None.

Projectile Recovery and Identification: Lead fragments (unidentified).

Gunshot Wound No. 5, Right Thigh, Non-Fatal
(Perforating skin and subcutaneous tissue)

Entry: Right anterolateral thigh.
Direction: Right to left, slightly posterior to anterior, inferior to superior.
Course: Skin and subcutaneous tissue.
Exit: Right anterior thigh.

Projectile Recovery and Identification: None.

Gunshot Wound No. 6, Left Thigh, Non-Fatal
(Penetrating soft tissue)

Entry: Left anteromedial thigh.
Direction: Right to left, slightly posterior to anterior, inferior to superior.
Course: Skin and subcutaneous tissue.
Exit: None.

Projectile Recovery and Identification: #00 buckshot.

JANE DOE NO. 1, aka NANCY LING PERRY

NOTE: The track of Gunshot Wound No. 5 can be aligned to the track of Gunshot Wound No. 6.

Gunshot Wound No. 7, Right Upper Arm, Non-Fatal
(Perforating soft tissue)

Entry: Medial aspect, right upper arm.

Direction: Left to right, slightly anterior to posterior, superior to inferior.

Course: Skin, subcutaneous tissue and muscle.

Exit: Posterior aspect, right upper arm.

Projectile Recovery None
and Identification:

DESCRIPTION OF GUNSHOT WOUNDS

Gunshot Wound No. 1, Back, Fatal

The entry wound, located 16 3/4 inches (42.5 cm) from the top of the head, and 4 1/8 inches (10.5 cm) to the right of the midline of the back, is circular, measuring 1/4 inch (0.6 cm) in diameter. The edges are smooth. There is a thin, surrounding abrasion rim. No powder marks are found. The wound track continues through skin, subcutaneous tissue and into muscles of the back where the bullet burst into many fragments producing fractures of the lateral aspects of the fifth, sixth and seventh ribs. A major fragment (a) passes anteriorly within the lateral muscles of the right chest wall and into the right breast producing a 2 1/2 inches (6.4 cm) external wound at the end of the track. Within the breast wound is found an irregular thin metallic fragment (later found to be a piece of unidentified copper jacket).

Another major fragment (b) passes into the chest cavity from right to left and slightly superiorly, passing through the inferior portion of the right upper lobe of lung, and exiting the thoracic cavity through the anterior fourth intercostal space. The hemorrhagic track continues through muscles and subcutaneous tissue, producing an irregular 3/8 x 1/8 inch (1.0 x 0.40 cm) wound in the skin 3/8 inch (1.0 cm) to the right of the midline and 12 1/4 inches (31.2 cm) from the top of the head. Along the cutaneous wound is found an irregular metallic fragment (later identified as a .223 caliber jacket and partial core). Other small fragments pass into the lateral aspect of the right lung. An

JANE DOE NO. 1, aka NANCY LING PERRY

unrecovered small fragment passes through the dome of the diaphragm on the right, and produces a 3 1/8 inches (8.0 cm) track along the superior aspect of the right lobe of liver.

Gunshot Wound No. 2, Back, Upper Right, Fatal

There are no powder marks around the 1/4 inch (0.6 cm) entrance wound with a thin abrasion rim, located 11 5/8 inches (29.5 cm) from the top of the head and 1 5/8 inches (4.2 cm) to the right of the midline of the back. The bullet passes through underlying skin and muscular tissue to burst into many fragments upon striking and fracturing the right scapula. There are two principal fragments: (a) and (b). A portion of fragment (a) consisting of bullet jacket material remains at the site of bullet disintegration, and a portion of fragment (a) produces a hemorrhagic track through muscles and subcutaneous tissue of the back, extending inferiorly and from right to left to exit through a jagged, nearly rectangular wound measuring 3/4 x 1/2 inch (2.0 x 1.2 cm) which is located 15 1/4 inches (38.6 cm) from the top of the head, and 1 1/8 inches (3.0 cm) to the right of the posterior midline of the body. There are no powder marks around this wound.

Fragment (b) produces a hemorrhagic track through muscles anterior to the scapula passing to the left and superiorly to pass into and through the first thoracic vertebra producing a 3/8 inch (1 cm) area of hemorrhagic disruption of the spinal cord at this site. There are additional areas of softening and hemorrhagic contusions of the spinal cord extending from the level of the 5th cervical vertebra to the 3rd thoracic vertebra. The wound track continues retropleurally on the left side to the midportion of the supraclavicular area on the left. Extensive retropleural hemorrhage and some mediastinal hemorrhage is continuous with the wound track. Fragment (b), (later identified as .223 caliber bullet jacket and partial core), is found within the muscular tissues above the left clavicle. There is a 5/8 inch (1.5 cm) rounded external wound in the charred muscle in this area. The overlying skin is missing.

Gunshot Wound No. 3, Right Hip, Potentially Fatal

The wound track begins in charred muscular tissue over the lateral aspect of the right hip. The overlying skin has been burned away. The track extends from right to left, angling upward at an angle of approximately 10 degrees and very slightly from anterior to posterior. The track continues through the muscular tissue on the inner aspect of the upper thigh on the right to exit through a markedly burned and charred area, after which the track produces hemorrhagic

JANE DOE NO. 1, aka NANCY LING PERRY

disruption of both labia majora and labia minora before passing into the left inner buttock area producing a palpable fracture of the left inferior ischial ramus, passing through muscular and fatty tissue with production of hemorrhagic disruption to exit along the lateral aspect of the left buttock through an irregular stellate wound measuring $7/8 \times 1/4$ inch (2.3×0.7 cm) in greatest dimension. Three small lead fragments (later unidentifiable) along the wound track are recovered.

Gunshot Wound No. 4, Right Thigh, Non-Fatal

The ovoid, $1/4 \times 3/8$ inch (0.8×1.1 cm) entrance wound has a thin abrasion rim, no powder marks, and is located about 1 inch (2.5 cm) above the knee on the posterolateral aspect of the right thigh. The wound track extends through skin, subcutaneous tissue and muscle, angling upward at approximately 10 degrees from the horizontal, and angling from right to left at about 45 degrees from the sagittal plane, passing through muscular tissues to produce a comminuted fracture of the lower third of the right femur. Lead fragments (later unidentifiable) are recovered from the fracture site and somewhat posteriorly.

Gunshot Wound No. 5, Right Thigh, Non-Fatal

The $5/8 \times 1/2$ inch (1.5×1.2 cm) slightly ovoid entrance wound has an abrasion rim and no surrounding powder marks. The entrance wound is located just to the right of the midline of the anterior thigh about 5 inches (12.7 cm) above the knee. The wound track passes within superficial subcutaneous tissue from right to left, very slightly posterior to anterior, and upward at an angle of about 10 degrees from the horizontal. The ragged $5/8 \times 1/2$ inch (1.5×1.2 cm) oval exit wound is located about 1 inch (2.5 cm) to the left of the entrance wound and slightly above. No projectile is recovered.

Gunshot Wound No. 6, Left Thigh, Non-Fatal

The somewhat irregular entrance wound, without powder marks and measuring slightly more than $5/16$ inch (0.8 cm) in greatest dimension, is located about 2 inches (5.1 cm) to the right of the anterior midline of the left thigh and about 6 inches (15.2 cm) above the knee. The track extends from right to left, slightly from posterior to anterior, and upward at an angle of about 10 degrees from the horizontal. The track continues through muscular tissue to end anterior to the right femur at which point a lead pellet is recovered (later identified as #00 buckshot).

JANE DOE NO. 1, aka NANCY LING PERRY

Note: The track of Gunshot Wound No. 5 can be aligned to track of Gunshot Wound No. 6.

Gunshot Wound No. 7, Right Upper Arm, Non-Fatal

The ovoid 1/4 x 3/8 inch (0.7 x 1.1 cm) entrance wound has a thin abrasion rim, no powder marks, and is located along the inner aspect of the right upper arm about 3 inches (7.6 cm) above the elbow. The track continues through subcutaneous tissue and muscle, with an irregular exit through charred muscular tissue along the posterior aspect of the arm just above the elbow. The overlying skin is missing. No major structures are noted to be injured.

MICROSCOPIC DESCRIPTION OF GUNSHOT WOUNDS

Gunshot Wound No. 1, Back, Fatal

Entrance: Inadvertently not taken for study.

Exit of portion of Fragment (a): (Slide GSW No. 1a) Tissue has extensive change from heat-induced coagulation. There is loss of much surface epithelium. Carbonized debris is noted along some surfaces. No distinct powder residue is identified. Collagenous breast stroma appears slightly increased in amount, and a few ducts are slightly dilated. A small amount of hemorrhage is noted in the deep fatty tissue.

Exit of portion of Fragment (b): (Slide GSW No. 1b) The surface epithelium is not present. An embedded piece of thin vegetable fiber is present. There is hemorrhage within underlying fatty and muscular tissue.

Gunshot Wound No. 2, Back, Upper Right, Fatal

Entrance: (Slide GSW No. 2 ENT) There are extensive coagulative changes due to heat. There is little remaining squamous epithelium. A hemorrhagic track extends into subcutaneous tissue. A dark fragment, embedded along the track, is made up of many dark amber translucent particles consistent with powder residue.

Exit of portion of Fragment (a): (Slide GSW No. 2a EXIT) Tissue has extensive changes due to heat. No powder residue is identified.

Gunshot Wound No. 3, Right Hip, Potentially Fatal

Entrance: No microscopic studies (entrance wound not

JANE DOE NO. 1, aka NANCY LING PERRY

identified.

Exit: (Slides GSW No. 3 EXIT) Marked tissue changes due to heat preclude confirmation of the nature of the wound. No powder residue is identified.

Gunshot Wound No. 4, Right Thigh, Non-Fatal

Entrance: (Slides GSW No. 4 ENT) Along the track there is carbonaceous debris and tiny bits of dark amber material which may or may not be powder residue. Also noted along the track are hair shafts and pieces of synthetic fiber. Hemorrhage is noted in the fatty tissue.

Gunshot Wound No. 5, Right Thigh, Non-Fatal

Entrance: (Slides GSW No. 5 ENT) Extensive changes of the epidermis due to heat preclude evaluation of the nature of the wound. There is much carbonized debris along surfaces. No distinct powder residue is identified.

Exit: (Slides GSW No. 5 EXIT) Extensive coagulation changes of epidermis and dermis preclude evaluation. No powder residue is identified.

Gunshot Wound No. 6, Left Thigh, Non-Fatal

Entrance: (Slides GSW No. 6 ENT) Heat changes of the epidermis and dermis preclude evaluation. Along the track, a vegetable fiber is noted and several hair shafts are noted in subcutaneous fat. No powder residue is identified.

Gunshot Wound No. 7, Right Upper Arm, Non-Fatal

Entrance and exit wounds inadvertently not taken for study.

POSTMORTEM DAMAGE DUE TO EXPLODING AMMUNITION

Located about 20 inches (50.8 cm) from the top of the head and 4 inches (10.2 cm) to the right of the midline of the back, there is a 5/8 x 3/8 inch (1.6 x 1.0 cm) irregular tear of the skin, beneath which is found in the subcutaneous tissue an irregular, thin metallic fragment (later identified as a .38 caliber special shell casing). No powder marks are identified around this tear of the skin. There is no vital reaction. To the left of this lesion and slightly above there are scattered similar superficial tears of the skin of the back up to 1/4 inch (0.6 cm) in greatest dimension from which no fragments are recovered.

JANE DOE NO. 1, aka NANCY LING PERRY

Along charred muscular tissue of the left anterior chest wall at about the anterior axillary line, there is a 1/4 inch (0.6 cm) slit in the skin. The slit continues through the muscles and through the underlying sixth intercostal space and through the diaphragm where an irregular metallic fragment (later identified as a piece of brass shell casing) is recovered from the anterior serosal surface of the stomach. A small lead fragment (later unidentifiable) is also found along the peritoneal cavity on the left side.

GENERAL EXTERNAL DESCRIPTION

The unembalmed body is that of a well-developed and apparently well-nourished Caucasian female of about 20 to 30 years of age, weighing 91 pounds (41.4 kg) and measuring 57 inches (144.8 cm) in length in its present condition. There are extensive skin changes due to heat. Large areas of the skin are missing and there is charring of underlying subcutaneous fat and muscle. Other large areas of skin have dark brownish discoloration and induration. There is reddening of the skin along the margins of the burned areas along the back of the right lower leg and along the sole of the left foot. Along the right side of the abdomen and continuing along the right side of the chest and the inner aspect of the right upper arm, the skin is largely spared. There is some reddening of this skin adjacent to burned areas. The skin of the anterior right thigh and the right foot is also largely spared. Much skin of the face is charred. There is extensive charring of the scalp down to and including underlying bone. A small amount of dark colored brown hair is found at the nape of the neck. There is extensive charring in the perineal area and the perianal area. No scars or tattoos are noted.

Primary Incision

The body is opened with the usual Y-shaped incision. The subcutaneous fat varies from 3/8 to 1 inch (1.0 to 2.6 cm) in thickness.

Body Cavities

The pericardial cavity contains a small amount of serosanguineous fluid. The right pleural space contains 300 to 400 ml of liquid and clotted blood. The left pleural space contains a small amount of serosanguineous fluid. There is extensive retropleural hemorrhage along the apical areas and about the upper thoracic vertebrae.

JANE DOE NO. 1, aka NANCY LING PERRY

Cardiovascular System

The 160 gram heart is of usual configuration. There is no dilatation of the chambers or hypertrophy of the muscular walls. The myocardium is reddish-brown, firm and homogeneous. Endocardial surfaces are smooth and glistening. No valvular abnormalities are noted. The coronary ostia have their usual origins and lead into patent right and left coronary arteries which have no significant atherosclerosis. No lesion of the major blood vessels is noted.

Respiratory System

The right lung weighs 440 grams and the left lung, 320 grams. There is some vascular congestion and edema, especially on the right side. A small amount of bloody fluid is noted within the bronchi. The anterior neck structures have no evidence of trauma. There is a small amount of bloody fluid within the pharynx, larynx and trachea. There is no swelling or inflammation of the mucosa.

Hemolymphatic System

The 60 gram spleen has a wrinkled, red capsule. The parenchyma is light red and slightly softened. No enlarged lymph nodes are found. The bone marrow and the thymus have no lesions.

Digestive System

The esophagus contains food particles. The stomach contains about 400 ml of yellow and tan small food particles and liquid. No residuals of medication are found. The mucosa is not inflamed. No lesion of the serosal surface is found. The small and large intestines and appendix have no lesion.

Hepatobiliary System

The 870 gram liver has a smooth capsule. The parenchyma has the usual lobular pattern and is pale reddish-tan. No lesion of the gallbladder is noted.

Urogenital System

The right kidney weighs 125 grams and the left kidney, 135 grams. The smooth cortical surfaces are pale reddish-tan. On sectioning, the kidney parenchyma is noted to be pale. The bladder contains only a very small amount of urine. The uterus is of usual size and configuration. The external cervical os is ovoid and appears nulliparous. The endometrium is thin, tan and velvety. No lesion of the tubes or

JANE DOE NO. 1, aka NANCY LING PERRY

ovaries is found. External genitalia have extensive changes due to heat.

Musculoskeletal System

Excluding the previously noted trauma, no lesion of the bones and muscles encountered in the autopsy is noted.

Endocrine System

The thyroid, parathyroid, pituitary, adrenals and pancreas are of usual size, color and consistency.

Head and Central Nervous System

Most of the scalp has been burned away and the underlying bone is charred in places. No skull fractures are noted. The sectioned brain and spinal cord are sent to the Forensic Neuropathologist for further study.

GENERAL MICROSCOPIC DESCRIPTION

Heart (Slides No. 18-6,11)

The left ventricular wall has some variation in myocardial cytoplasmic staining, vascular congestion and no muscular hypertrophy. One fairly large intramyocardial coronary artery has eccentric proliferative subendothelial fibrosis with about 80 to 90 percent luminal restriction. Adjacent myocardium has a small area of fibrosis. Arteries in other areas have only mild vasoproliferative changes. The right ventricular wall has some interstitial edema and pronounced vascular congestion.

Lungs (Slides No. 18-9,10)

There is vascular congestion and marked intra-alveolar hemorrhage. There is no acute inflammation, tumor, or other disease. There is no granulomatous change or foreign material.

Spleen (Slide No. 18-8)

Normal white pulp, red pulp, trabecular and capsular structures are seen. There is some congestion of the sinusoids, but no unusual cellularity.

Liver (Slides No. 18-3,4)

The usual lobular architecture is present with patent

JANE DOE NO. 1, aka NANCY LING PERRY

sinusoids having moderate vascular congestion. There is very mild local chronic triaditis. No hemorrhage or acute inflammation is seen. One liver margin has fragmentation without any significant hemorrhage.

Stomach (Slide No. 18-14)

Only superficial mucosal autolysis is seen with moderate vascular congestion.

Small Intestine (Slide No. 18-15)

There is subtotal autolysis. There is no preexisting lesion seen.

Colon (Slide No. 18-16)

There is marked mucosal autolysis. A tangential section has no mucosal or muscular abnormality.

Kidneys (Slides No. 18-12,13)

There is diffuse vascular congestion and no inflammation, tumor, or hemorrhage. The congested glomeruli are of usual size and number. The tubules have no necrosis or any unusual material in their lumina. The arterial walls have minimal thickening.

Uterus (Slide No. 18-2)

There is a fairly dense stroma of the basalis of the endometrium with early branching of glands. The myometrium has the usual smooth muscle layers.

Ovary (Slide No. 18-5)

There is the usual ovarian stroma for this age with many small and large developing graafian follicles, and corpora albicantia. There is no tumor, hemorrhage, or inflammation.

Adrenals (Slide No. 18-7)

The cortical cells are replete with lipids and the medullary cells have no abnormality. Some diffuse vascular congestion is seen.

Spinal Cord (Slides 18-1,18)

A longitudinal section from the cervical spinal cord to the disrupted thoracic area has meningeal hemorrhage with an irregular hemorrhagic inferior margin. In another section,

JANE DOE NO. 1, aka NANCY LING PERRY

there is hemorrhagic disruption with embedded small bits of bone.

FORENSIC NEUROPATHOLOGY EXAMINATION

Gross Findings

The dorsolateral, occipital and basilar portions of dura present some brownish blood on both the epidural and subdural surfaces which can be readily removed without leaving any pigment or neomembrane. The dural sinuses contain no thrombus.

The cerebrum has been previously cut into five coronal sections. The leptomeninges have some subarachnoid blood staining over the medial aspect of the right parieto-occipital lobes, but there is no actual blood clot. The color is dark reddish-brown. This covers an area about 6 cm in diameter. The leptomeninges are otherwise thin and transparent. The superficial blood vessels contain a minimal amount of blood. The cerebral convolutions are flattened throughout. There is no subfalcial herniation. The cut surfaces have no pathologic findings. The parahippocampal gyri cannot be evaluated due to distortions.

The cerebrum is further sectioned coronally revealing no evidence of hemorrhage, necrosis or pathologic defect. The sulci and the ventricles are narrowed.

The brain stem and cerebellum have also been previously horizontally sectioned revealing no gross lesion. Further sections also show no gross lesion. The cerebellar tonsils have moderate herniation without necrosis.

The spinal cord consists of two segments. A 3.0 cm segment from the upper cervical region has no remarkable findings. The second segment, from the lower portion down to the conus measures 19 cm in length. The leptomeninges, the configuration, size and consistency of the cord and the cut surfaces are not remarkable.

Microscopic Description

Sections have subarachnoid hemorrhage, generalized congestion and extravasation. Hemolysis is present in the more superficial portions of the cerebrum. The nerve cells have swollen nuclei with small nucleoli. The nuclear chromatin and the nuclear membranes are indistinct. The Nissl bodies have almost completely disappeared. The matrix is homogenized. In the basal ganglia and thalami, the nuclei have

JANE DOE NO. 1, aka NANCY LING PERRY

pyknosis. Some nerve cells have central chromatolysis. There is, however, much better preservation of the Nissl bodies although some are homogenized.

The cerebellum has acute swelling of the Purkinje cells with almost dissolution of their nuclei. The nucleoli are still visible. The spinal cord has some central chromatolysis of the anterior horn cells. The Nissl bodies are mostly intact in nerve cells having distinct chromatin and nuclear membranes. Some nuclear membranes are rather indistinct. The fiber columns have microcysts. The nerve roots have a spongy appearance. The blood vessels have endothelial thickening.

Diagnoses

1. Essentially normal brain with postmortem heat-induced changes.
2. Submitted portions of spinal cord with postmortem heat-induced changes.

FORENSIC RADIOLOGY EXAMINATION

Skull

A single AP view of the skull is within normal limits. There are no significant findings.

Thorax

Fractures of the 3rd, 4th, 5th, 6th and 7th ribs on the right are noted. There are fractures of the 1st, 2nd, 3rd and possibly the 4th thoracic vertebrae. Vertebral fractures are vertical, more to the right side. A spray of both thin and dense metallic fragments is noted on the right side of the mid and lower thorax. The largest of these fragments is irregular, measuring 3/4 x 1/2 inch (1.9 x 1.3 cm) in greatest dimension, and is found just to the right of the midline and at about the level of the 5th thoracic vertebra. Another spray of both dense and thin metallic fragments stretches across the thorax at the level of the 1st and 2nd thoracic vertebrae. Just above the left clavicle there is an irregular principal fragment measuring 3/4 x 3/8 inch (1.9 x 1.0 cm) in the projection of the film. Over the lower left lateral aspect of the thorax is projected a 1/2 inch (1.3 cm) irregular thin metallic fragment.

JANE DOE NO. 1, aka NANCY LING PERRY

Lumbar Vertebrae

Several metallic fragments are seen projected in the right upper and left upper quadrants. The vertebrae appear to be within normal limits and free of trauma.

Pelvis

No fracture is discerned on the right or on the left. Multiple metallic densities are seen overlying the lower portion of the pelvis and over the thigh areas on each side. Some fragments are dense and some appear thin. The largest of these is 5/8 inch (1.6 cm) in greatest dimension and overlies the left inferior pubic ramus.

Extremities

A comminuted fracture of the distal end of the right femur is surrounded by a number of dense metallic fragments, the largest of which is 1/2 inch (1.3 cm) in greatest dimension in the projection of the film. A rounded 3/8 inch (1.0 cm) metallic density is noted over the proximal third of the diaphysis of the left femur. There is no associated fracture. Metallic densities are seen in the area of the right elbow with no associated fracture. Films of remaining extremities have no identifiable fractures.

FORENSIC ODONTOLOGY EXAMINATION

The maxilla and mandible of Jane Doe No. 1, Case No. 74-6761, are examined. There is generally good arch formation and occlusion is Class I. Tooth No. 20 is in buccal crossbite and Tooth No. 29 approximates end to end occlusion. The maxillary arch has no restorations, while four mandibular amalgam fillings are present, as depicted on the postmortem chart.

The maxilla, mandible, and postmortem radiographs are compared to antemortem radiographs and dental charts labelled "Nancy Ling." The postmortem radiographs are dated 5-18-74 and consist of two lateral jaw films, fourteen periapical films and four bite-wing films. There are two antemortem bite-wing radiographs dated 12-16-67 and two antemortem bite-wings dated 9-12-66. The most recent entry on the dental charts is 6-21-68 and the earliest is 8-8-51.

The fillings described in the dental charts are found in the jaws in the locations described. In both cases, there are no maxillary fillings. As between antemortem and postmortem radiographs, the MOD filling in Tooth No. 19 shows numerous

JANE DOE NO. 1, aka NANCY LING PERRY

distinctive features which are identifiable in both sets of radiographs, and which superimpose well. Tooth No. 20 also has distinctive features which are evident in both sets of radiographs. While the presence of Teeth No. 1 and No. 32 cannot be confirmed by the antemortem bite-wings, the presence of Teeth No. 16 and No. 17 is evident in both antemortem and postmortem radiographs. On comparison, similarities in anatomical features are noted, such as the configuration of the outer contour of the enamel on Tooth No. 18 and the marginal ridge relationship of Teeth No. 28 and No. 29. There is also good superimposability of the bite-wing radiographs as to tooth size and position.

Conclusion

The jaws and postmortem radiographs of Jane Doe No. 1, Case No. 74-6761 are a positive match with the radiographs and dental charts labelled "Nancy Ling."

FORENSIC TOXICOLOGY EXAMINATION

| <u>Specimen</u> | <u>Compound</u> | <u>Result</u> |
|--------------------------------|---|--------------------------------|
| <u>Blood</u> | Ethanol, Barbiturates, and Neutral Drugs | Neg. |
| | Carbon monoxide (CO) saturation | 11% |
| | Morphine, Codeine and Cocaine | Neg. |
| | Salicylates, Trichlorethanol, Ethchlorvynol, Basic Drugs, Diphenhydramine, and Oxazepam | Neg. |
| | "Tear Gas" (i.e., Chloroacetophenone (CN) and O-chlorobenzalmalonitrile (CS)) | Neg. |
| | Gasoline | Neg. |
| | Cyanide determination | Neg. |
| | <u>Liver</u> | Phenothiazines and Basic Drugs |
| Barbiturates and Neutral Drugs | | Neg. |
| Gasoline | | Neg. |
| <u>Lung</u> | "Tear Gas" (i.e., Chloroacetophenone (CN) and O-chlorobenzalmalonitrile (CS)) | Neg. |

JANE DOE NO. 1, aka NANCY LING PERRY

| <u>Specimen</u> | <u>Compound</u> | <u>Result</u> |
|-----------------|-------------------------------|---------------|
| <u>Bile</u> | Morphine, Codeine and Cocaine | Neg. |
| <u>Kidney</u> | Amphetamines | Neg. |

FORENSIC BIOLOGY EXAMINATION

Material Submitted

Blood for Typing

Findings

Type: B
Rh: Positive

Material Submitted

Vaginal and Anal Smears

Findings

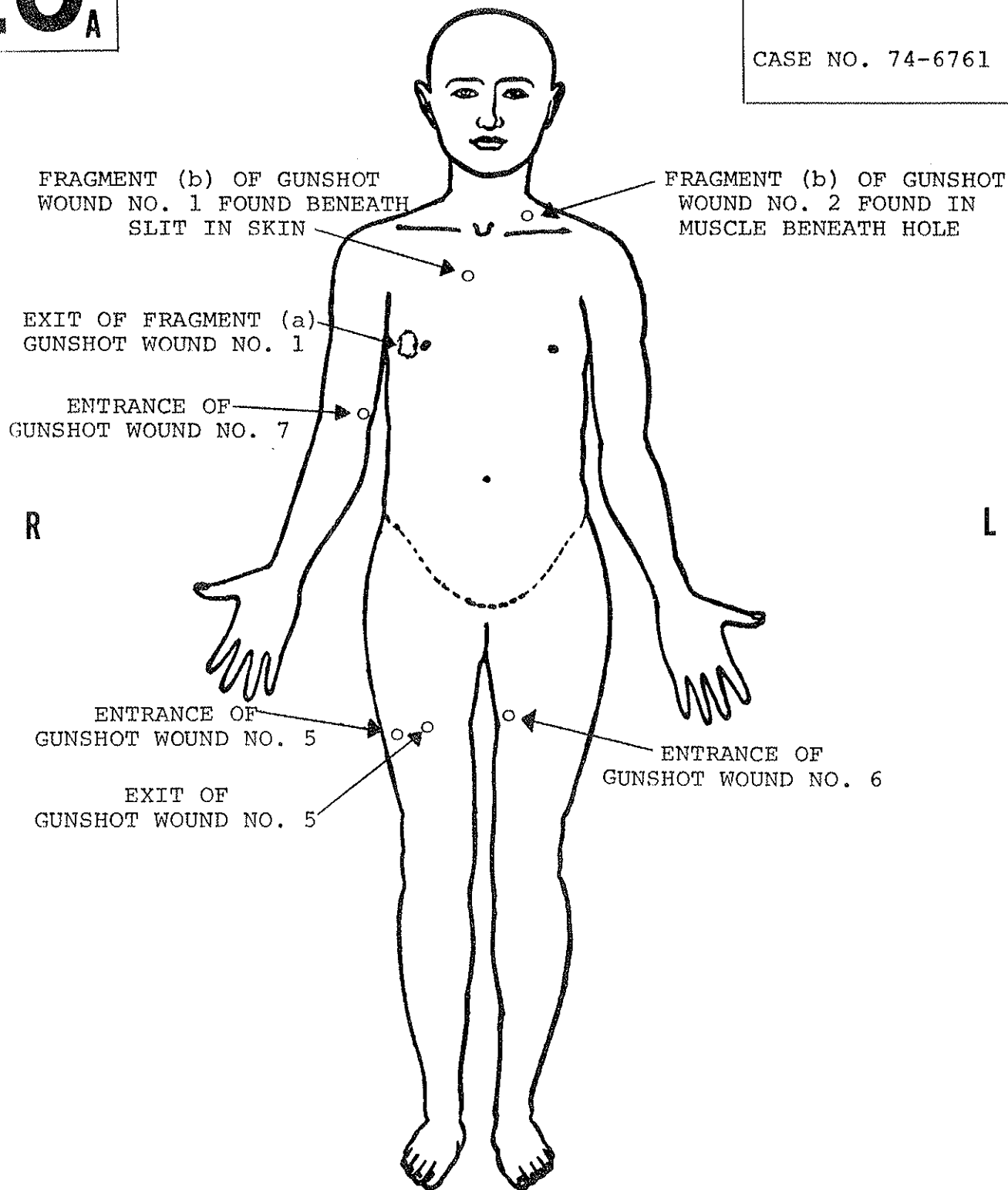
Acid phosphatase - no reaction
No sperm seen

20
A

JANE DOE NO. 1, aka

NANCY LING PERRY

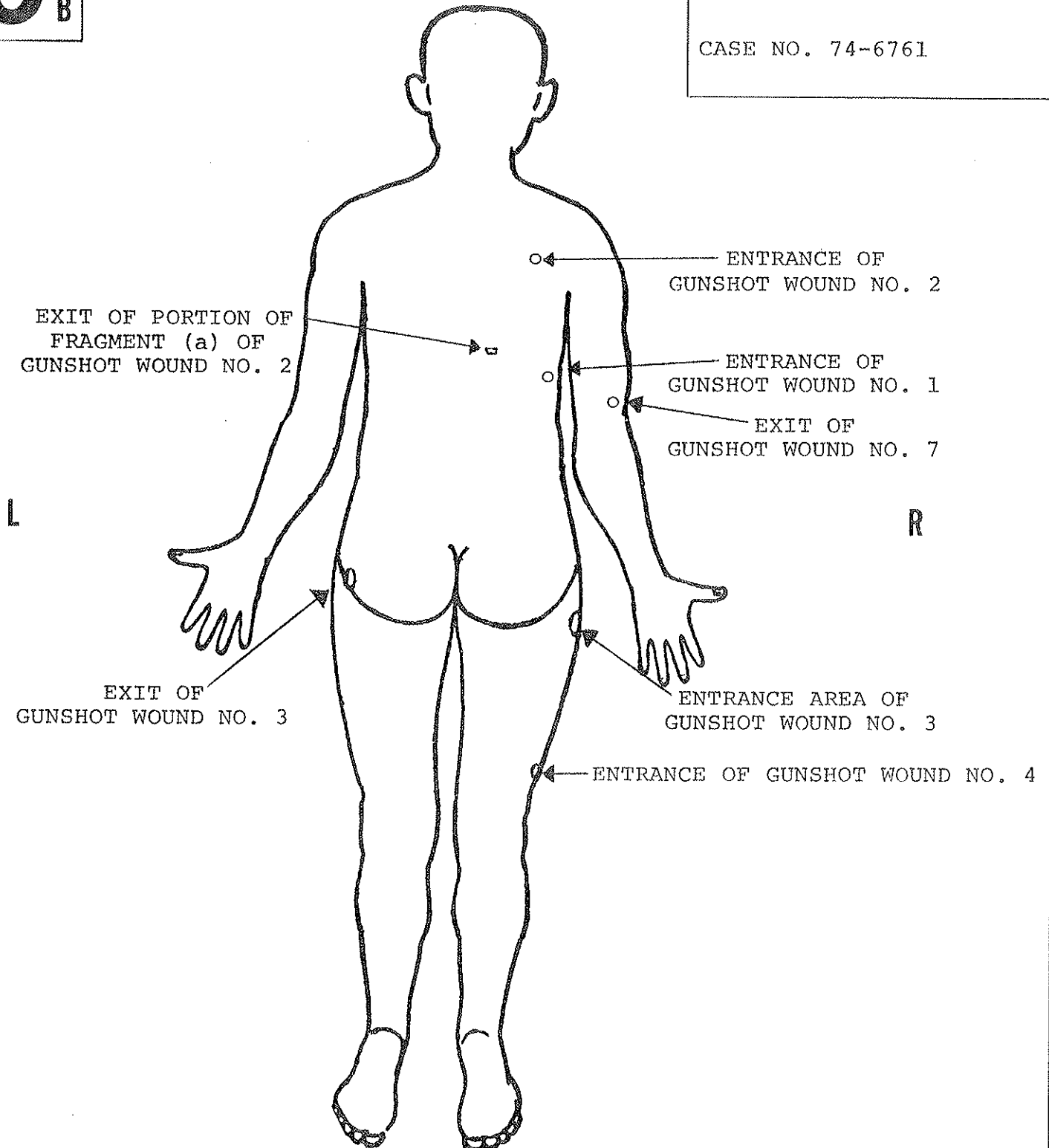
CASE NO. 74-6761



_____ M.D.
Deputy Medical Examiner.

20
B

JANE DOE NO. 1, aka
NANCY LING PERRY
CASE NO. 74-6761



| | |
|-------------------------|------|
| | M.D. |
| Deputy Medical Examiner | |

COUNTY OF LOS ANGELES
DEPARTMENT OF CHIEF MEDICAL EXAMINER-CORONER

PATIENT: JANE DOE NO. 1, aka NANCY LING PERRY

Date May 18, 1974

File No. 74-6761

| | | | | | | | | | | | | | | | |
|--|--------|----|----|----|----|----|----|----|----|----|----|----|----|--------|--------|
| 1 | 2 | 3 | 4 | 5 | 6 | 7 | 8 | 9 | 10 | 11 | 12 | 13 | 14 | 15 | 16 |
| UPPER LEFT | | | | | | | | | | | | | | | |
| 16 | 15 | 14 | 13 | 12 | 11 | 10 | 9 | 8 | 7 | 6 | 5 | 4 | 3 | 2 | 1 |
| LOWER LEFT | | | | | | | | | | | | | | | |
| 32 | 31 | 30 | 29 | 28 | 27 | 26 | 25 | 24 | 23 | 22 | 21 | 20 | 19 | 18 | 17 |
| Normal, but oper- culum over distal | Caries | A. | A. | | | | | | | | | A. | A. | Normal | Caries |
| <p>Nos. 6 through 13 are normal and well aligned except for:</p> <p>No. 6 has a gingival cleft; and</p> <p>slight labial position- ing of No. 7;</p> <p>Nos. 11 and 12 have gingival abrasions</p> | | | | | | | | | | | | | | | |

LEGEND:
Amalgam: A; Gold: G; Silicate: S;
Acrylic: Ac; Missing Teeth: X

JANE DOE NO. 1, aka NANCY LING PERRY

REPORT OF AT-SCENE AND FOLLOW-UP INVESTIGATION

Doe No. 1, later identified as Jane Doe No. 1, aka Nancy Ling Perry, was found lying in a prone position, head in a northeasterly direction, south of the southwest corner, and on the outside of the burned-out structure. A search of the perimetric area surrounding the body of approximately 12 inches by the Coroner's Senior Investigator failed to reveal any evidence that would aid in identification. Found on the ground beneath the decedent were remnants of burned clothing, and what appeared to be a .30 caliber magazine containing an unknown amount of ammunition. Adjacent to the body was found what appeared to be the burned remnants of a gas mask.

The decedent was brought to the Forensic Science Center at 2305 hours on May 17, 1974, by the Coroner's Senior Investigator and Coroner's Investigator.

Physical Description

Female Caucasian; 21 plus years of age; charred
Height: approximately 57 inches
Weight: approximately 91 pounds

Clothing on Body

The articles of burned clothing were inventoried and released to the Scientific Investigation Division of the Los Angeles Police Department on May 18, 1974 at 1610 hours.

Personal Property Found on Body

The articles of personal property were inventoried and released to the Scientific Investigation Division of the Los Angeles Police Department on May 18, 1974 at 1600 hours.

Additional Evidence Found on Body

Additional evidence was found on the body by the Coroner's Medical Photographer on May 17, 1974, at 2350 hours, while photographing the body at the Forensic Science Center. Evidence was inventoried and later released to the Scientific Investigation Division of the Los Angeles Police Department on May 20, 1974 at 1430 hours.

COUNTY OF LOS ANGELES
DEPARTMENT OF CHIEF MEDICAL EXAMINER-CORONER
LOS ANGELES, CALIFORNIA 90033

JANE DOE NO. 2, aka ANGELA ATWOOD

Case No. 74-6762

This is to certify that the autopsy on the body of Angela Atwood was performed at The Forensic Science Center, Los Angeles, by the staff of the Department of Chief Medical Examiner-Coroner, on May 18, 1974.

CAUSE OF DEATH: THERMAL BURNS AND SMOKE INHALATION

The detailed medical findings, opinions and conclusions required by Section 27491 of the Government Code of California are attached.

Thomas T. Noguchi, M.D.
Chief Medical Examiner-Coroner

ANATOMICAL SUMMARY

1. Respiratory mucosal hyperemia.
2. Sooty material on respiratory mucosa.
3. Pulmonary vascular congestion and edema.
4. Thermal burns.
5. Postmortem charring of body.

Note: No gunshot wounds.

GENERAL EXTERNAL DESCRIPTION

The body is that of an unembalmed, well-developed and apparently well-nourished white female appearing about 20 to 30 years of age. The body is markedly burned with extensive cutaneous charring, and charring down to the bones and visceral cavities, such that the estimation of antemortem weight and height is difficult. She is measured at 56 inches (142 cm) in length, and 72 pounds (32.7 kg); prior to death, she would have been somewhat larger. The scalp is devoid of hair with burning of the scalp to the point that the skull is exposed and much of the superior aspect of the skull is burned away, showing burned and heat-coagulated brain tissue. The face is markedly burned and charred. The body surfaces are burned and charred, except for an area along the anterior mid-chest and abdomen. The left lateral trunk area is extensively charred with exposure of the pleural and peritoneal cavities on the lateral aspect and charring of the organs in these areas. The distal portions of the lower legs and feet are missing. The hands are extensively charred. No tattoos, scars or deformities are identified.

Primary Incision

The body is opened with the usual Y-shaped incision revealing a moderate subcutaneous fat and normal musculature, although the musculature is heat-coagulated and charred in many areas.

Body Cavities

The right pleural cavity contains a small amount of serosanguineous fluid. The left pleural cavity contains charred tissue debris with marked charring of the lateral pleura. The peritoneal cavity has smooth and shiny surfaces with some charring of the left posterolateral aspect.

Cardiovascular System

The heart weighs 200 grams and is of usual configuration. The coronary ostia have their usual origins and lead into

JANE DOE NO. 2, aka ANGELA ATWOOD

patent right and left coronary arteries which have insignificant atherosclerosis. The atria, valves, endocardium, myocardium, and ventricles are unremarkable. The aorta has the usual branches and has very minimal atherosclerosis. The major veins are unremarkable. Blood in vessels has a fairly bright red color.

Neck Organs

The pharynx, larynx and trachea have their usual anatomic location and relationship. There is no evidence of compression, hemorrhage or muscular abnormality. The lumina of the respiratory passages have copious amounts of black, sooty material mixed with mucus. There is some submucosal edema and moderate hyperemia. There is no foreign body obstruction.

Respiratory System

The right lung weighs 600 grams and the left lung, 300 grams. The charred lateral and posterior portions of the left lung are firm, black-brown and contracted. The right lung is firm with a dark red coloration as is the uninvolved part of the left lung. There is vascular congestion and edema of the lungs. Bronchial mucosa is hyperemic and covered by a moderate amount of mucus mixed with soot. The pulmonary vessels have some fluid blood. No nonthermal trauma or preexisting lesion is found.

Digestive System

The esophagus is unremarkable. The stomach contains about 140 ml of tan to yellow-orange fluid and particulate matter. Some of the particulate material, when smashed between the fingers, has the consistency of milk curds or cottage cheese. The gastric mucosa is autolyzed but has no lesions. The small and large intestines and appendix are unremarkable except for the superficial charring of the bowel along the left lateral aspect.

Hepatobiliary System

The liver weighs 990 grams, has a smooth red-brown, capsular surface, and on section has a red-brown lobular architecture. The gallbladder has a small amount of dark green bile and has no mucosal lesion. The extrahepatic biliary ducts are patent.

Urogenital System

The right kidney weighs 140 grams and the left kidney, 150

JANE DOE NO. 2, aka ANGELA ATWOOD

grams. The cortical surfaces are smooth and pale red-brown. The kidneys have mild cortical pallor with 1 cm thick cortices and no hemorrhage or other lesion. The urinary bladder is a small, thick-walled structure which contains a minute amount of urine and has no mucosal lesion. The uterus, fallopian tubes and ovaries are in the usual position and have the usual size and relationship. The uterus has an 8-9 mm thick myometrium and a scant, velvety pale tan endometrium. The cervical os is small and round, consistent with a nulliparous state. There are small cervical erosions.

Hemolymphatic System

The spleen weighs 40 grams, has a wrinkled, slightly heat-coagulated capsule and a firm, medium red parenchyma. The lymph nodes, bone marrow and thymus are unremarkable.

Musculoskeletal System

There is charring of the left lateral ribs, skull, legs and hands, as previously noted. No antemortem fracture is found.

Endocrine System

The thyroid is of usual size and has red-brown parenchyma. The parathyroids are unremarkable. The adrenals are in the usual location, and have dark brown medullae and thin, golden-yellow cortices. The pituitary is in the sella turcica and has no abnormality. The pancreas is of average size with the usual pink-tan lobular pattern.

Central Nervous System

Portions of the scalp and calvarium have been burned away. The protruding brain is coagulated and slightly hemorrhagic. The heat changes are on the superior and slightly posterior aspects. The anterior and basal aspects of the frontal and temporal lobes are relatively intact. There is no evidence of antemortem damage. The brain, sectioned, is sent to the Forensic Neuropathologist for further study.

GENERAL MICROSCOPIC DESCRIPTION

Heart (Slides No. 21-1,2,3)

Vascular congestion, especially of the right ventricular myocardium, is seen. The intramural coronary vessels have no significant changes. There is very mild interstitial edema. Moderate numbers of myocardial cells with increased eosinophilia are seen. No inflammatory cells of significance are noted.

JANE DOE NO. 2, aka ANGELA ATWOOD

Lungs (Slides No. 21-4,5)

Intense vascular congestion and fairly copious dense edema are present. The edema fluid contains many non-pigmented macrophages. Small bronchi have some patchy superficial cellular necrosis without associated peribronchial hyperemia. There appears to be focal, increased goblet cell activity, part of which may be autolytic. No acute inflammatory cells are noted. No crystalline foreign material or granulomata are seen.

Lower Trachea (Slide No. 21-6)

There is mucosal and some submucosal autolysis with marked submucosal hyperemia in almost all areas. The muscular and adventitial layers are hyperemic and have postmortem bacterial growth.

Upper Trachea (Slide No. 21-7)

Total mucosal and extensive submucosal (lamina propria) autolysis is present. Pronounced vascular hyperemia is evident. The muscular and adventitial layers also have vascular congestion, as well as postmortem bacterial growth in the latter.

Main Bronchus (Right) (Slide No. 21-8)

There is autolysis of most of the mucosa and some of the submucosa. Areas of submucosa have pronounced hyperemia. The glands appear normal and the muscularis has only vascular congestion. The adventitia has vascular congestion.

Larynx (Slide No. 21-9)

There is autolysis of the mucosa and most of the submucosal areas. Small particles of sooty material are found along remaining mucosa. There is vascular congestion of all the layers of the larynx, but no vasculitis, thrombosis, nor glandular abnormality.

Epiglottis (Slide No. 21-10)

There is total mucosal and extensive submucosal autolysis. Sooty particles are present. The submucosal and musculo-cartilaginous layers have less autolysis, but have marked hyperemia.

Spleen (Slide No. 21-11)

The white pulp, red pulp, trabecular and capsular structures

JANE DOE NO. 2, aka ANGELA ATWOOD

have no abnormality. The cellular components are normal.

Liver (Slide No. 21-12)

The usual lobular and sinusoidal patterns are seen with some vascular congestion. No fibrosis, bile duct proliferation, necrosis, inflammation or granulomata are seen.

Pancreas (Slide No. 21-13)

A normal lobular pattern is noted with no increased fibrous tissue or acute inflammation. There is early ductal, mucosal, and parenchymal autolysis. Islet cells are present and are unremarkable.

Stomach (Slide No. 21-14)

There is extensive mucosal autolysis and marked submucosal vascular congestion.

Kidneys (Slides No. 21-15,16)

The usual cortical and medullary pattern is seen. The glomeruli are in normal numbers and have no enlargement, fibrosis, synechia, or other change except for engorgement of the capillaries. The blood vessels of the medullae are hyperemic. There is no fibrosis or inflammation. The tubular structures have no inflammation, dilation, necrosis or other abnormality.

Uterus (Slide No. 21-17)

A normal endometrium, consisting mainly of basalis, is noted. The myometrium has the usual muscular wall with no inflammation, tumor or hemorrhage.

Ovary (Slide No. 21-18)

There are a few dilated follicles. Some vascular congestion is noted. The stroma has no inflammation or hemorrhage.

Thyroid (Slide No. 21-19)

There is a normal follicular pattern with large and small thyroid follicles filled with colloid. There is a slight patchy increase of connective tissue. A few small aggregates of lymphocytes are noted.

JANE DOE NO. 2, aka ANGELA ATWOOD

FORENSIC NEUROPATHOLOGY EXAMINATION

Gross Findings

The dura is not included.

The brain consists of irregular fragments of tissue, part of which has a dark gray discoloration. The external and superior portions of the cerebrum are actually charred. The entire specimen, including the similarly altered brain stem and cerebellum, weighs 665 grams. The recognizable portions of the external surfaces of the cerebrum have transparent leptomeninges. Some darkened areas probably contain some blood pigment. In further sectioning, there is some preservation of the cortical pattern, white matter and portions of the basal ganglia, which consist of the striatum and a portion of the thalamus. The brain stem and the cerebellum are slightly better preserved, but on section the tissue crumbles readily. There is apparent herniation of the cerebellar tonsils.

The spinal cord with the dura measures 35 cm. The dura has a dark gray discoloration throughout. The leptomeninges have a brownish discoloration, but there is no actual blood clot. The spinal cord fits the dural sheath rather tightly. The lower end of the cord is at the lumbosacral junction. In some portions of the cord the usual pattern is not seen on multiple transverse sections. There is no blood pigment within the substance of the cord.

Microscopic Findings

Sections have congestion and hemorrhages with hemolysis in some of the blood vessels. There is quite marked endothelial swelling. In the cerebral cortex, the nerve cells have acute swelling with almost homogenization of the nuclei. The cytoplasm is practically invisible and it disappears into the homogenized matrix. In the cerebral white matter, the glial cells have marked swelling of their nuclei and have a lighter staining than usual. In the basal ganglia, the large nerve cells have very poor staining, and many are ghost cells. The smaller cells and glial cells have swollen nuclei. The matrix is also homogenized. In the medulla, the nerve fibers are swollen and granular. In the olives, the nerve cells have complete homogenization with pyknotic nuclei and eosinophilic cytoplasm. The tissue from the deeper portions of the specimen is better preserved than the more superficial portions. The spinal cord has pyknosis and homogenization of the anterior horn cells which are also eosinophilic. There are mononuclear cells in the posterior sulcus. The fibers are swollen and granular.

JANE DOE NO. 2, aka ANGELA ATWOOD

There are clumps of bacteria.

Diagnoses

1. Essentially normal brain with postmortem heat-induced changes.
2. Essentially normal spinal cord with postmortem heat-induced changes.

FORENSIC RADIOLOGY EXAMINATION

Skull

A single AP view of the skull has a partial absence of the right side of the calvarium and a mid convexity fracture on the left. The soft tissues are covered by small superficial metallic fragments, some of which are round, apparently representing melted metal.

Thorax

A left mid clavicular fracture and a fracture of the antero-posterior aspect of the left 2nd rib are noted. The lateral aspects of ribs 3 to 11 are missing, associated with a soft tissue defect in this area. The visualized thoracic vertebrae are unremarkable. The left lung is seen in virtually total collapse; the right in partial collapse. Projected over the thorax are numerous tiny metallic densities, many of which are round.

Abdomen

There is no evidence of bony trauma. Scattered, fine metallic densities are noted. An ammunition primer and a primer anvil are projected over the left lower quadrant.

Extremities

There is an oblique fracture of the proximal diaphysis of the humerus with only slight displacement. The fracture has a geographic pattern, consistent with a heat fracture. There are heat-fracture amputations of the distal ends of the right tibia and fibula. The distal fragments and foot are not seen. There is a geographic-type fracture of the distal diaphysis of the left femur, with posterior dislocation of the distal fragment of approximately two bone widths. Overlying the soft tissue adjacent to the mid portion of the left femoral diaphysis, there is an ammunition primer. Multiple tiny metallic densities are projected over bones and soft tissues of all extremities. No other bony abnormalities are identified.

JANE DOE NO. 2, aka ANGELA ATWOOD

FORENSIC ODONTOLOGY EXAMINATION

The maxilla and mandible of Jane Doe No. 2, Case No. 74-6762, are examined. Occlusion is "cusp to cusp", and extensive restorative dentistry is noted, much of which is gold with plastic facings. The maxilla, mandible, and postmortem radiographs are compared to antemortem radiographs and dental charts labelled "Angel de Angelis", and a more recent chart which bears the name "Angela Atwood." The postmortem radiographs are dated 5-18-74 and consist of two lateral jaw films, fourteen periapical films, and four bite-wings. The antemortem films consist of two bite-wings dated 6-16-67, and a series of ten periapical and two bite-wing films dated 3-5-66. The more recent chart bears an entry on 1-8-72, and relates to surgery in the area of Tooth No. 13. The earlier chart contains extensive entries describing restorative procedures. The most recent entry is 10-1-68 and the earliest is 3-5-66. A telephone call to the restorative dentist in New Jersey verifies the interpretation of chart abbreviations.

On comparison, there are numerous concordant points, many of which are distinctive. No unexplainable discrepancies are noted. Construction of veneer crowns in all four quadrants is described in the antemortem records and visualized in the jaws of Jane Doe No. 2 in the locations described. Specific fillings, such as distolingual of Tooth No. 6, and mesial of Tooth No. 7, are also affirmatively cross-matched. Similarities in root shape are noted and representative radiographs from both sets of records superimpose well. The removal of Tooth No. 13 is verified in the postmortem material. Distinctive findings such as the virtual absence of pulp chamber in Tooth No. 28 are visible in both sets of records.

Conclusion

The jaws and postmortem radiographs of Jane Doe No. 2, Case No. 74-6762, are a positive match with the radiographs and dental charts labelled "Angel de Angelis" and "Angela Atwood."

FORENSIC TOXICOLOGY EXAMINATION

| <u>Specimen</u> | <u>Compound</u> | <u>Result</u> |
|-----------------|--|---------------|
| <u>Blood</u> | Ethanol, Barbiturates, and Neutral Drugs | Neg. |
| | Carbon monoxide (CO) saturation | 17% |
| | Morphine, Codeine and Cocaine | Neg. |

JANE DOE NO. 2, aka ANGELA ATWOOD

| <u>Specimen</u> | <u>Compound</u> | <u>Result</u> |
|-----------------------------|--|----------------------|
| <u>Blood</u> | Amphetamines | Neg. |
| | Salicylates, Trichlorethanol, Ethchlorvynol, Basic Drugs, Diphenhydramine and Oxazepam | Neg. |
| | "Tear Gas" (i.e., Chloroacetophenone (CN) and O-chlorobenzalmalonitrile (CS) | Neg. |
| | Gasoline | Neg. |
| | Cyanide determination | 59 mcg per 100 ml |
| <u>Liver</u> | Phenothiazines and Basic Drugs | Neg. |
| | Barbiturates and Neutral Drugs | Neg. |
| <u>Lung</u> | "Tear Gas" (i.e., Chloroacetophenone (CN) and O-chlorobenzalmalonitrile (CS) | Neg. |
| <u>Bile</u> | Morphine, Codeine and Cocaine | Neg. |
| <u>Gastric Contents</u> | Cyanide determination | Neg. |

FORENSIC BIOLOGY EXAMINATION

Material Submitted

Blood for Typing

Findings

Type: AB
Rh: Positive

Material Submitted

Vaginal and Anal Smears

Findings

Acid phosphatase - no reaction
No sperm seen

COUNTY OF LOS ANGELES
DEPARTMENT OF CHIEF MEDICAL EXAMINER-CORONER

NAME JANE DOE NO. 2, aka ANGELA ATWOOD Date May 18, 1974 File No. 74-6762

| | 1 | 2 | 3 | 4 | 5 | 6 | 7 | 8 | 9 | 10 | 11 | 12 | 13 | 14 | 15 | 16 |
|-------------|------------------------|---------------------------------------|--------------------------------|--|---|---------------|----|---------------------------------------|---------------------------------------|------------------------|----|----|----|----|----|----|
| UPPER RIGHT | | | | | | | | | | | | | | | | |
| | Not clinically evident | Full gold crowns with acrylic facings | Porcelain fused to gold crowns | Probably S, but affected by heat | Charred to gingival line; roots present | Normal | A. | Missing | Full gold crowns with acrylic facings | Not clinically evident | | | | | | |
| LOWER RIGHT | | | | | | | | | | | | | | | | |
| | Not clinically evident | Full gold crowns with acrylic facings | A. | Normal, except for moderate crowding with No. 24 to labial at mesial aspect; | No. 26: M silicate D silicate | Enamel defect | A. | Full gold crowns with acrylic facings | Not clinically evident | | | | | | | |
| UPPER LEFT | | | | | | | | | | | | | | | | |
| LOWER LEFT | | | | | | | | | | | | | | | | |

LEGEND:

Amalgam: A; Gold: G; Silicate: S;
Acrylic: Ac; Missing Teeth: X

JANE DOE NO. 2, aka ANGELA ATWOOD

REPORT OF AT-SCENE AND FOLLOW-UP INVESTIGATION

Doe No. 2, later identified as Jane Doe No. 2, aka Angela Atwood, was found lying in a prone position, head in a southwesterly direction, just inside the southwest corner of the burned-out structure. The body was noted to be extensively charred. Adjacent to the body was what appeared to be the burned remnants of a gas mask. This evidence was taken by the investigating officer of the Los Angeles Police Department at the scene.

The decedent was brought to the Forensic Science Center at 2305 hours on May 17, 1974 by the Coroner's Senior Investigator and Investigator.

Physical Description

Female Caucasian; 21 plus years of age; charred
Height: 56 inches
Weight: 72 pounds

Clothing on Body

The articles of burned clothing were inventoried and released to the Scientific Investigation Division of the Los Angeles Police Department at 1610 hours on May 18, 1974.

Personal Property Found on Body

The articles of personal property were inventoried and released to the Scientific Investigation Division of the Los Angeles Police Department on May 18, 1974 at 1600 hours, with the exception of \$1.86 in currency and coin, which is retained in the Coroner's custody until completion of the investigation.

Additional Evidence Found on Body

Additional evidence was found on the body by the Coroner's Medical Photographer on May 18, 1974, between the hours of 0045 and 0110, while photographing the body at the Forensic Science Center. The evidence was inventoried and later released to the Scientific Investigation Division of the Los Angeles Police Department on May 20, 1974 at 1430 hours.

COUNTY OF LOS ANGELES
DEPARTMENT OF CHIEF MEDICAL EXAMINER-CORONER
LOS ANGELES, CALIFORNIA 90033

JOHN DOE NO. 3, aka WILLIAM LAWTON WOLFE Case No. 74-6763

This is to certify that the autopsy on the body of William Lawton Wolfe was performed at The Forensic Science Center, Los Angeles, by the staff of the Department of Chief Medical Examiner-Coroner, on May 18, 1974.

CAUSE OF DEATH: SMOKE INHALATION AND EXTENSIVE
BURNS

The detailed medical findings, opinions and conclusions required by Section 27491 of the Government Code of California are attached.

Thomas T. Noguchi, M.D.
Chief Medical Examiner-Coroner

ANATOMICAL SUMMARY

1. Thermal burns, extensive.
2. Pulmonary congestion and edema.
3. Acute generalized passive hyperemia, marked.
4. Postmortem heat-induced fractures of left tibia and fibula.
5. Postmortem damage from exploding ammunition.

Note: No gunshot wounds.

DESCRIPTION OF BURNS

There are extensive skin changes due to heat involving most external surfaces of the body. There is some sparing of the lower anterior chest wall, the lower abdomen, and a strip of skin along the anterior aspect of the lower left thigh. Along the margins of the spared area of the chest wall, there is irregular reddening of the skin. Reddening of the skin is also noted along the inner aspect of the left forearm. In other areas where skin is present, there is dark brown induration. There are large areas of skin loss with charring of underlying subcutaneous fat and muscle involving the entire head, both lower legs and feet, the posterior aspect of the left thigh, the lateral aspect of the right side of the torso, with the continuation onto the lateral, and portions of the anterior aspects of the right thigh. The external genitalia have been spared. In areas in which there has been loss of the upper layers of skin, there is some reddish mottling of underlying tissue. All extremities are stiff and partly flexed.

POSTMORTEM DAMAGE FROM EXPLODING AMMUNITION

Tiny, irregular, metallic fragments are noted along many surfaces of the body. Occasional, rounded fragments appear to have been previously molten metal. Along the upper outer aspect of the left thigh, a brass empty cartridge case has been driven perpendicularly into the skin and subcutaneous tissue. No reaction at this site is identified.

Other separate metallic objects from exploding ammunition, located by x-ray, are recovered.

An ammunition primer (No. 1) is removed from subcutaneous tissue of the upper outer aspect of the left thigh. No vital reaction at this site is found.

An ammunition primer (No. 2) is recovered from subcutaneous tissue of the posterior aspect of the mid upper left arm. There is no vital reaction.

JOHN DOE NO. 3, aka WILLIAM LAWTON WOLFE

An ammunition primer (No. 3) is recovered from subcutaneous tissue of the left lower anterolateral chest wall. There is no associated vital reaction.

An unfired bullet (No. 4) is located along the posterior aspect of the mid-portion of the left upper arm (later identified as an unfired, 9 mm hollow-point bullet). There is no bullet track or vital reaction in this area.

An unfired bullet (No. 5) is found within the subcutaneous tissue of the upper portion of the right thigh (later identified as an unfired, 9 mm hollow-point bullet). There is no associated bullet track or vital reaction.

GENERAL EXTERNAL DESCRIPTION

The unembalmed body is that of a well-developed and apparently well-nourished Caucasian male of approximately 20 to 30 years of age, weighing 121 pounds (55 kg), and measuring 66 inches (169 cm) in length in the present condition. No identifying features such as scars, tattoos or deformities are noted. No other postmortem or antemortem trauma is noted. No lesion of the external genitalia is noted. The penis is circumcised.

Primary Incision

The body is opened with the usual Y-shaped incision. The subcutaneous fatty tissue is up to 1 cm thick.

Body Cavities

The pleural, peritoneal and pericardial cavities are lined by smooth, glistening membranes. There are physiologic amounts of fluid within these spaces.

Cardiovascular System

The 300 gram heart has the usual contour. There is no dilatation of the chambers or hypertrophy of the muscular walls. The myocardium is firm, reddish-brown and homogeneous with no focal lesions. The endocardium is smooth and glistening. The valve leaflets are thin and pliable. No valve lesion is noted. No abnormal communications are found. The coronary arteries have thin, pliable walls. The aorta has no significant atherosclerosis and is not dilated.

Respiratory System

The right lung weighs 710 grams and the left, 640 grams. Dependent portions of both lungs are dark red, and abundant

JOHN DOE NO. 3, aka WILLIAM LAWTON WOLFE

frothy fluid and blood exudes on minimal pressure. The remaining parenchyma is pinkish-tan and crepitant. The pulmonary vessels have no lesion. There is no sooty material in the airways, but the mucosa of the larynx, trachea, and principal bronchi is markedly hyperemic and coated with viscous mucus. The neck structures have no evidence of trauma.

Hemolymphatic System

The blood within vessels is cherry red. The bone marrow is rusty red and firm. The thymus has atrophic and fatty changes consistent with age. The 100 gram spleen has a bluish, thin intact capsule. The cut surfaces are dark red and somewhat soft. The follicular pattern is not unusual. No enlarged lymph nodes are found.

Digestive System

The esophagus has a smooth, greyish-white mucosa. The stomach contains about 100 ml of tan mucoid material within which no identifiable food particles are seen. No residuals of medication are identified. The mucosa is not inflamed. No lesion of the internal or external surfaces of the small and large intestines is found. The appendix is present and is of usual appearance.

Hepatobiliary System

The 1100 gram liver has a smooth, intact capsule and sharp edges. The cut surfaces are firm and reddish-brown, without fibrosis. The extrahepatic biliary ducts have no lesion.

Urogenital System

The right kidney weighs 120 grams and the left kidney, 130 grams. The capsules strip with ease from smooth greyish-brown cortical surfaces. The cut surfaces ooze a large amount of blood and have sharp corticomedullary demarcation. No focal lesions are identified. The pelves, ureters and urinary bladder have no unusual features. The urinary bladder contains about 25 ml of clear urine. The renal vessels are patent and of usual location. The prostate is symmetrical and not enlarged. The testes are in the scrotal sac and the tubules tease easily. No lesion of the penis is noted.

Musculoskeletal System

The bones and muscles encountered in the performance of the autopsy have no distinct lesions. No antemortem fractures are found. The muscles have a brighter reddish coloration

JOHN DOE NO. 3, aka WILLIAM LAWTON WOLFE

than is usually noted.

Endocrine System

The thyroid gland is smooth, uniform and symmetrical. It is not enlarged. The parathyroid glands are not enlarged. The adrenals have normal cortical thickness and no lesion is noted. The pituitary is not unusual. The pancreas is of usual size, color, and consistency.

Head and Central Nervous System

On reflection of pieces of unburned scalp, no underlying hemorrhages are found. The skull cap is removed in the usual fashion. There is no epidural, subdural or subarachnoid blood. No distinct lesion of the external surfaces of the brain is seen. The sectioned brain and spinal cord are submitted to the Forensic Neuropathologist for further study.

GENERAL MICROSCOPIC DESCRIPTION

Heart (Slides No. 12, 14, 15, 16)

The sections of the heart including the anterior wall of the left ventricle (Slide No. 12), the posterior wall of the left ventricle (Slide No. 16), the lower septum (Slide No. 14) and the area of the atrioventricular node (Slide No. 15) have changes of heat coagulation. The fibers appear shrunken, opaque and mottled. The nuclei are small, mottled and hyperchromatic; some have entirely disappeared. In the least changed areas, as in the anterior wall of the heart and in some focal areas of the septum, normal histology is noted.

Lungs (Slides No. 9, 10, 11, 12, 13)

In representative sections of the upper, middle and lower lobes of the right lung and of the upper and lower lobes of the left lung, alveolar capillaries, as well as the pulmonary and bronchial blood vessels, are markedly dilated and engorged with blood. Many erythrocytes are within the adjacent alveolar sacs. Many alveoli contain a dense homogeneous eosinophilic proteinaceous fluid, as well as some desquamated lining cells. The bronchial lining cells are extensively desquamated. There are a few small focal areas of interstitial fibrosis, as well as an accumulation of pigmented histiocytes. There is no acute inflammatory reaction. There are no foreign body granulomata. There is no embolic material in alveolar capillaries.

JOHN DOE NO. 3, aka WILLIAM LAWTON WOLFE

Trachea and Larynx (Slides No. 1, 2, 3, 4, 5)

In the five sections of the larynx and trachea, including the epiglottis, there is desquamated mucosa. The lamina propria appears slightly edematous and is heavily infiltrated by lymphocytes. The blood vessels are engorged.

Spleen (Slide No. 17)

A section has no significant histopathologic changes. The capsule and the trabecula are not unusual. The blood vessels are slightly dilated and engorged with erythrocytes. The sinusoids contain erythrocytes, as well as the usual population of cells. The white pulp is composed of prominent lymphocytic elements and a central arteriole.

Liver (Slide No. 19)

A section has no significant histopathologic changes. The lobular architecture is apparent, with thin-walled, non-dilated, central veins from which radiating sinusoids and cords of hepatocytes are noted. The hepatocytes contain round to ovoid nuclei with visible nucleoli. The portal triads contain no excess of lymphocytes, and normal elements of bile ducts, lymphatics, hepatic artery and portal vein are seen. There is no fibrous tissue proliferation. No foreign body reaction is found.

Pancreas (Slides No. 20, 21)

The two sections have extensive autolytic changes. There is no significant inflammatory reaction or hemorrhage.

Small Intestine (Slide No. 13)

A section has postmortem autolysis, and no significant histopathologic changes.

Tongue (Slide No. 18)

A longitudinal section, which includes the distal end, has extensive coagulation of the tip with complete destruction of the covering mucosa and exposure of the underlying bundles of heat-coagulated skeletal muscle. The blood vessels of the tip of the tongue are markedly dilated and engorged with laked blood. Towards the base, the mucosa is present. No glands are noted.

JOHN DOE NO. 3, aka WILLIAM LAWTON WOLFE

Kidneys (Slides No. 22, 23)

The sections of the right kidney (Slide No. 23) and left kidney (Slide No. 22) have extensive heat-coagulation change, mainly of the tubules. The interstitial tissue is markedly reduced and the convoluted tubules are markedly edematous and eosinophilic with obliteration of the lumina. The glomerular capillaries are engorged with erythrocytes. No significant inflammatory reaction is present.

Prostate Gland (Slide No. 22)

A section, including the prostatic urethra, is composed of fibromuscular connective tissue containing numerous ducts. The ductal lining cells are desquamated. No nodules are noted. The urethra is lined by transitional epithelium, and the underlying lamina propria contains scattered chronic inflammatory cells and dilated blood vessels, engorged with blood.

Testis (Slide No. 24)

A section, including the epididymis, has a tunica albuginea composed of the usual dense fibrous connective tissue. The seminiferous tubules contain the usual number of spermatogenic cells and contain some central mature spermatozoa. The loose interstitial tissue contains the usual number of interstitial cells. No significant histopathologic changes are present. Some of the ductuli of the epididymis contain clumps of spermatozoa, as well as a few multinucleated desquamated cells.

Spermatic Cord (Slide No. 16)

A cross section has some heat-coagulation changes. The blood vessels are tortuous and dilated, engorged with blood and dense eosinophilic proteinaceous material. The vas deferens has the usual muscular coat, and most of the lining single-layer, tall, columnar epithelial cells are desquamated. Some intact fronds are noted projecting into the lumen. Bundles of muscles have heat-coagulation changes. Nerve bundles are unremarkable.

Muscle (Slide No. 6)

A section from the right thigh (site of unfired bullet) has heat coagulation change. The fibers are pale and shrunken. Most of the nuclei are small or indistinct.

JOHN DOE NO. 3, aka WILLIAM LAWTON WOLFE

Skin (Slides No. 7, 8)

The two sections of the burned skin, including subcutaneous fat and underlying skeletal muscle of the left arm (Slide No. 8) and right thigh (Slide No. 7), from which unfired bullets were recovered, have full-thickness coagulation necrosis of the epidermis, dermis, subcutaneous fat and muscle, with complete destruction of the skin and exposure of the subcutaneum. Some adnexa, represented by hair follicles, remain identifiable. There is no hemorrhage or inflammatory reaction.

FORENSIC NEUROPATHOLOGY EXAMINATION

Gross Findings

The dorsolateral, occipital and basilar portions of dura have charred blood over the epidural surfaces. Dorsolaterally, in the frontal regions, the subdural surface has a minimal amount of similar brownish to black discoloration. There is no recognizable blood clot per se or pathologic defects. The dural sinuses contain postmortem clots which are partially desiccated. The cerebrum has been previously cut into seven coronal sections. The leptomeninges are thin and transparent. The cerebral convolutions are completely flattened. The blood vessels are not remarkable. The structures at the base of the brain cannot be evaluated due to previous sectioning. The previously cut surfaces have fairly well recognizable structures. There is heat coagulation of most of the tissue. In further sections of the cerebrum, the peripheral portions of the tissue are extensively altered. They have a granular appearance on the cut surfaces. The sulci and ventricles are narrowed. There is no evidence of any old lesions or pathologic defects. The basal ganglia and thalami are better preserved than the cerebral cortex and white matter.

The brain stem and cerebellum have been previously sectioned. They have a similar appearance to the cerebrum.

Further sections have no additional lesion.

The entire spinal cord with dura is included. The dura has a dark brown-gray discoloration on the external surface. The subdural surface of the dura is smooth, glistening and has no discoloration. The leptomeninges are thin and transparent. Multiple transverse sections have no internal lesion.

JOHN DOE NO. 3, aka WILLIAM LAWTON WOLFE

Microscopic Description

All sections have congestion and extravasation with hemolysis of some of the blood within the lumina of the blood vessels. There is swelling of the endothelium. The cerebral cortex has acute swelling of the nerve cells. The nuclei have indistinct staining of the chromatin, although the nucleoli are still visible but are smaller than usual. The cytoplasm has a varying degree of homogenization. In most cells there is lysis of the Nissl bodies. In the basal ganglia, there is better preservation of nerve cells; however, there is some acute swelling with indistinct cytoplasm. The nuclei of the glial cells are swollen and the matrices are homogenized. In the spinal cord, occasional nerve cells of the anterior horns have central chromatolysis. The Nissl bodies in most of the nerve cells are well-preserved. The white matter of the spinal cord has marked vacuolization. In the substantia nigra, the pigmented cells are swollen, and some have indistinct nuclei. The pigment is fairly well preserved.

Diagnoses

1. Dura, partially charred.
2. Essentially normal brain with postmortem heat-induced changes.
3. Essentially normal spinal cord with postmortem heat-induced changes.

FORENSIC RADIOLOGY EXAMINATION

Most films have fine metallic densities located over soft tissues and along surfaces.

Skull

No fractures or significant metallic fragments are found.

Thorax and Abdomen

No fractures or large metallic fragments are found. An ammunition primer is noted over the soft tissue of the lateral aspect of the left lower thorax.

Upper Extremities

No fractures are demonstrated. Overlying the proximal portion of the left humerus and soft tissue there is an intact bullet, an ammunition primer, a primer anvil and a thin metallic fragment consistent with cartridge case material.

JOHN DOE NO. 3, aka WILLIAM LAWTON WOLFE

No bony lesion is seen in this area. Superficial, fine metallic densities of varying size are noted over the right humerus and overlying the soft tissues of the right forearm.

Pelvis and Lower Extremities

No antemortem fractures are identified. Tiny metallic densities are noted over the pubic rami bilaterally. Projected over the mid diaphyseal area of the right femur, there is what appears to be an intact bullet and tiny metallic densities. No lesion of the adjacent bone is identified. Over the lateral aspect of the left hip area, an ammunition primer is noted along with fine metallic densities. There appears to have been a partial disarticulation of the right knee joint (due to heat-contracted muscles). The broken distal ends of the left tibia and fibula have a geographic pattern consistent with fire fractures.

FORENSIC ODONTOLOGY EXAMINATION

The maxilla and mandible of John Doe No. 3, Case No. 74-6763, are examined. The teeth are well aligned and there is a good Class I occlusal relationship. The decedent has received considerable dental care, as evidenced by a number of fillings and a gold and porcelain bridge in the mandibular right quadrant.

The maxilla, mandible, and postmortem radiographs are compared to antemortem radiographs and dental charts labelled "William Wolfe" and "Willie Wolfe." The postmortem radiographs consist of fourteen periapical films and four bite-wing films. The antemortem radiographs are as follows: one periapical film dated 12-22-73, a series of sixteen periapical and four bite-wing films dated 10-31-73, and two bite-wing films dated 5-5-72. Charts are available from two dentists and the most recent chart entry is 2-1-74.

On comparison, there is almost an infinite number of matching points between the antemortem and postmortem evidence. The numerous entries on the dental charts describe dental restorations which are also found in the teeth of John Doe No. 3. Moreover, there is a corresponding time sequence. For example, the chart shows that Fillings No. 2-0 and No. 12 MOF are about two years old. John Doe No. 3 has these fillings in the appropriate teeth and their clinical appearance is consistent with that of two year old fillings. A number of matching points are highly characteristic. For example, the 12-22-73 radiograph of Tooth No. 19 superimposes extremely well with the corresponding postmortem film and has a highly distinctive contour, permitting detailed

JOHN DOE NO. 3, aka WILLIAM LAWTON WOLFE

comparison. Moreover, the William Wolfe chart contains a description of the fixed bridge which matches the bridge in John Doe No. 3's mouth, both as to teeth involved and details of construction.

Conclusion

The jaws and postmortem radiographs of John Doe No. 3, Case No. 74-6763, are a positive match with the radiographs and dental charts labelled "William Wolfe" and "Willie Wolfe."

FORENSIC TOXICOLOGY EXAMINATION

| <u>Specimen</u> | <u>Compound</u> | <u>Result</u> |
|-----------------|--|---------------|
| <u>Blood</u> | Ethanol, Barbiturates and Neutral Drugs | Neg. |
| | Amphetamines | Neg. |
| | Morphine, Codeine and Cocaine | Neg. |
| | Salicylates, Trichlorethanol, Ethchlorvynol, Basic Drugs, Diphenhydramine and Oxazepam | Neg. |
| | "Tear Gas" (i.e., Chloroacetophenone (CN) and O-chlorobenzalmalononitrile (CS)) | Neg. |
| | Carbon monoxide (CO) saturation | 36.5% |
| | Cyanide determination | Neg. |
| <u>Liver</u> | Phenothiazines and Basic Drugs | Neg. |
| | Barbiturates and Neutral Drugs | Neg. |
| <u>Lung</u> | "Tear Gas" (i.e., Chloroacetophenone (CN) and O-chlorobenzalmalononitrile (CS)) | Neg. |
| <u>Bile</u> | Morphine, Codeine and Cocaine | Neg. |

JOHN DOE NO. 3, aka WILLIAM LAWTON WOLFE

FORENSIC BIOLOGY EXAMINATION

Material Submitted

Blood for Typing

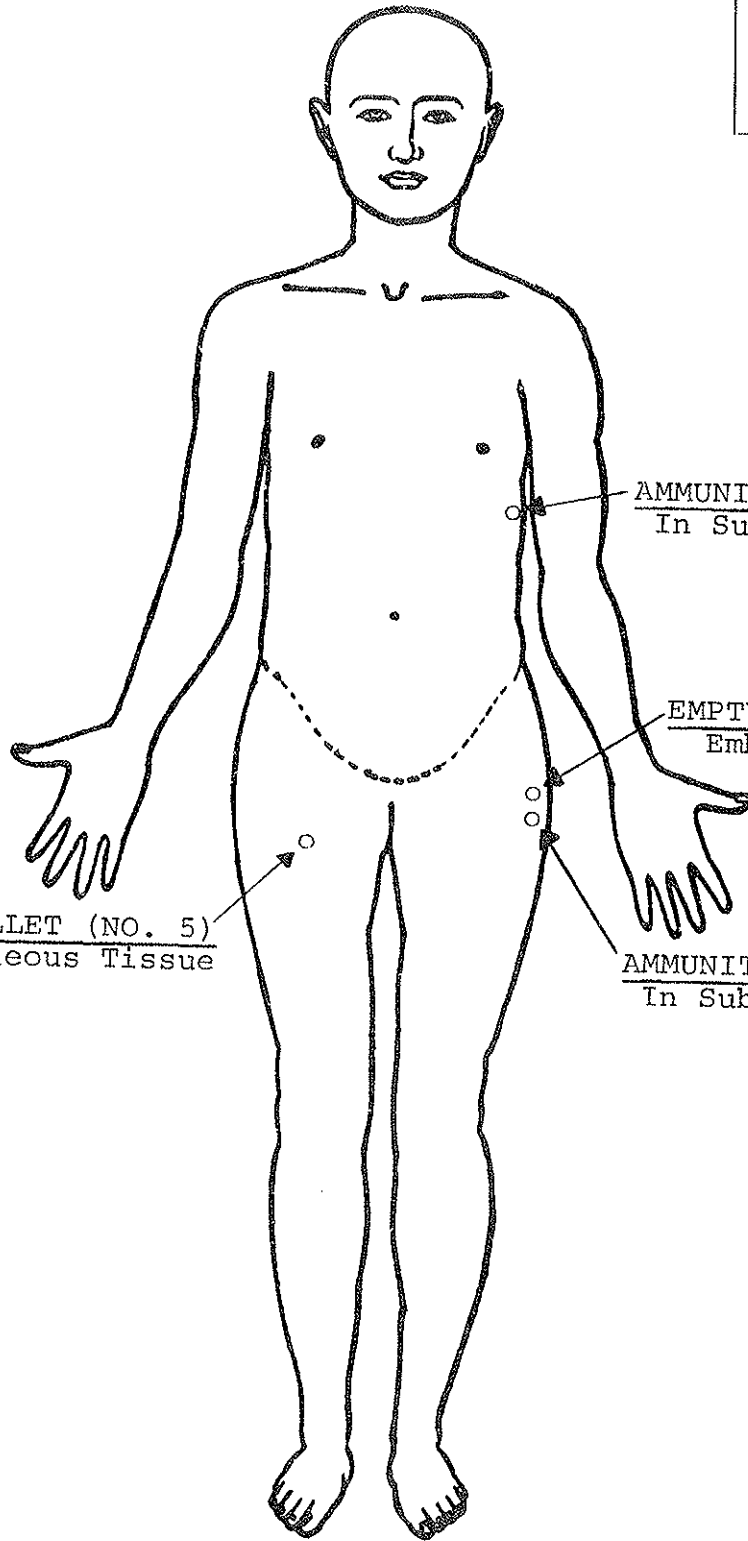
Findings

Type: O

Rh: Positive

20_A

JOHN DOE NO. 3, aka
WILLIAM LAWTON WOLFE
CASE NO. 74-6763



AMMUNITION PRIMER (NO. 3)
In Subcutaneous Tissue

EMPTY CARTRIDGE CASE
Embedded in Skin

UNFIRED BULLET (NO. 5)
In Subcutaneous Tissue

AMMUNITION PRIMER (NO. 1)
In Subcutaneous Tissue

20 B

JOHN DOE NO. 3, aka
WILLIAM LAWTON WOLFE

CASE NO. 74-6763

UNFIRED BULLET (NO.4)

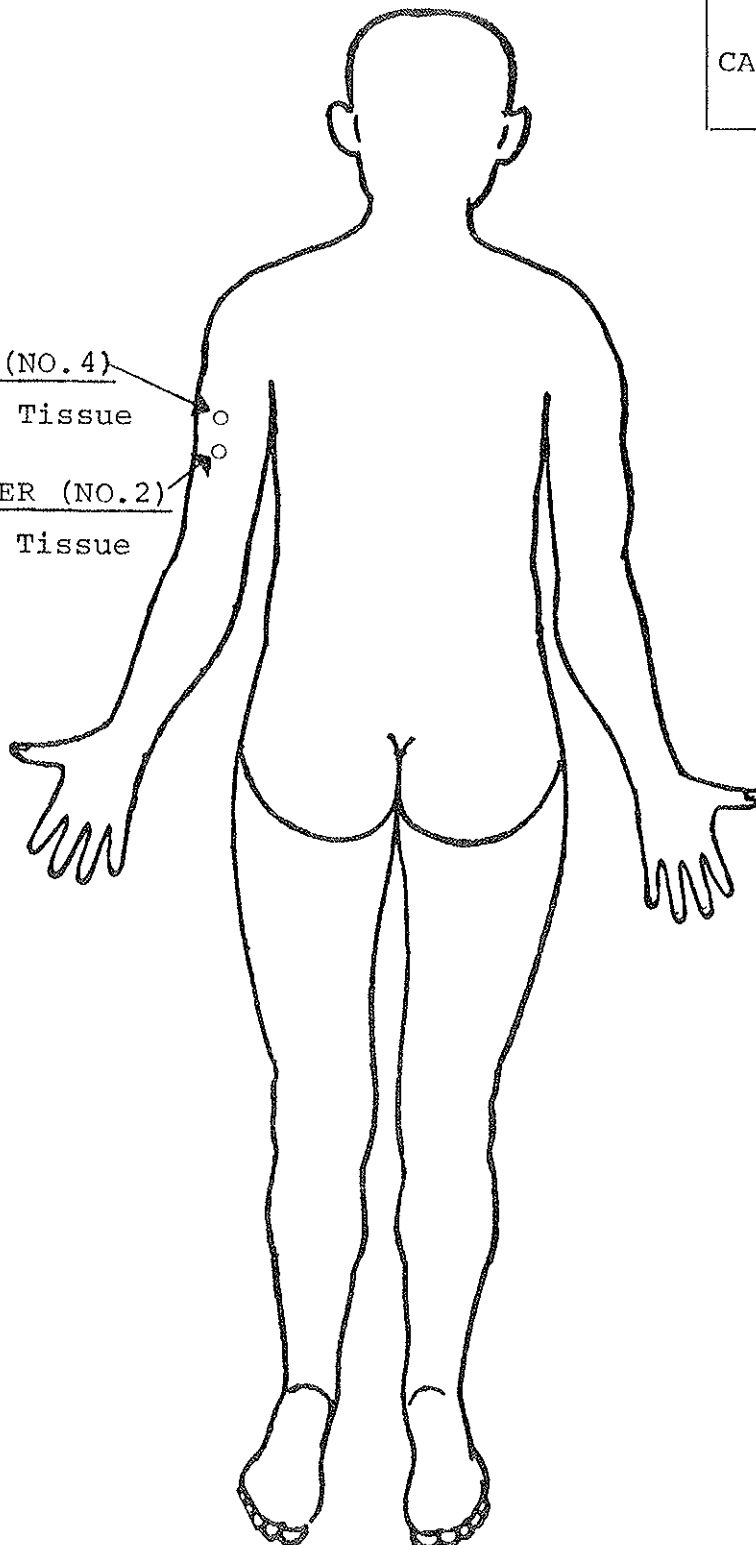
In Subcutaneous Tissue

AMMUNITION PRIMER (NO.2)

In Subcutaneous Tissue

L

R



COUNTY OF LOS ANGELES
DEPARTMENT OF CHIEF MEDICAL EXAMINER-CORONER

NAME JOHN DOE NO. 3, aka WILLIAM LAWTON WOLFE Date May 18, 1974 File No. 74-6763

| UPPER RIGHT | 1 | 2 | 3 | 4 | 5 | 6 | 7 | 8 | 9 | 10 | 11 | 12 | 13 | 14 | 15 | 16 | UPPER LEFT |
|---|----|----|----|----|----|----|----|----|----|----|----|----|----|----|----|----|------------|
| | | | | | | | | | | | | | | | | | |
| LOWER RIGHT | 32 | 31 | 30 | 29 | 28 | 27 | 26 | 25 | 24 | 23 | 22 | 21 | 20 | 19 | 18 | 17 | LOWER LEFT |
| | | | | | | | | | | | | | | | | | |
| <p>LEGEND:</p> <p>Amalgam: A; Gold: G; Silicate: S; Acrylic: Ac; Missing Teeth: X</p> | | | | | | | | | | | | | | | | | |

JOHN DOE NO. 3, aka WILLIAM LAWTON WOLFE

REPORT OF AT-SCENE AND FOLLOW-UP INVESTIGATION

Doe No. 3, later identified as John Doe No. 3, aka William Lawton Wolfe, was found lying in a prone position inside the southeast corner of the structure, just to the west of Doe No. 4; the head was facing south, near the air vent. The body was noted to be extensively charred.

The decedent was brought to the Forensic Science Center at 2305 hours on May 17, 1974 by the Coroner's Senior Investigator and Investigator.

Physical Description

Male Caucasian; approximately 23 years of age; charred
Height: 66 inches
Weight: 121 pounds

Clothing on Body

The articles of burned clothing were inventoried and released to the Scientific Investigation Division of the Los Angeles Police Department on May 18, 1974 at 1610 hours.

Personal Property Found on Body

The articles of personal property were inventoried and released to the Scientific Investigation Division of the Los Angeles Police Department on May 18, 1974 at 1600 hours, with the exception of \$127.28 in currency and coin, which is retained in the Coroner's custody until completion of the investigation.

Additional Evidence Found on Body

Additional evidence was found on the body by the Coroner's Medical Photographer on May 18, 1974, at 0140 hours, while photographing the body at the Forensic Science Center. The evidence was inventoried and later released to the Scientific Investigation Division of the Los Angeles Police Department on May 20, 1974 at 1430 hours.

COUNTY OF LOS ANGELES
DEPARTMENT OF CHIEF MEDICAL EXAMINER-CORONER
LOS ANGELES, CALIFORNIA 90033

JOHN DOE NO. 4, aka DONALD DeFREEZE

Case No. 74-6764

This is to certify that the autopsy on the body of Donald DeFreeze was performed at The Forensic Science Center, Los Angeles, by the staff of the Department of Chief Medical Examiner-Coroner, on May 18, 1974.

CAUSE OF DEATH: GUNSHOT WOUND THROUGH HEAD

The detailed medical findings, opinions and conclusions required by Section 27491 of the Government Code of California are attached.

Thomas T. Noguchi, M.D.
Chief Medical Examiner-Coroner

ANATOMICAL SUMMARY

GUNSHOT WOUNDS

1. Gunshot wound of head, through brain, fatal.
2. Gunshot wound of skin and subcutaneous tissue, left chest wall, non-fatal.

OTHER PERTINENT FINDINGS

1. Thermal burns of mouth, pharynx and larynx.
2. Pulmonary vascular congestion and edema.
3. Moderate atherosclerosis of aorta.
4. Appendectomy, status remote.
5. Old bullet, right thigh.

POSTMORTEM CHANGES

1. Postmortem burns of skin, subcutaneous tissue and muscle.
2. Postmortem skin and subcutaneous damage from exploding ammunition.

SUMMARY OF GUNSHOT WOUNDS

Gunshot Wound No. 1, Head, Fatal

Entry: Right temporal area.

Direction: Right to left, slightly anterior to posterior, and inferior to superior.

Course: Scalp on right, skull, both cerebral hemispheres, skull on left, and scalp on left.

Exit: Left temporoparietal area.

Projectile Recovery and Identification: Small fragments of bullet recovered. (Analysis is in progress.)

Gunshot Wound No. 2, Left Chest Wall, Non-Fatal

Entry: Posterolateral aspect, left lower chest wall.

Direction: Left to right, anterior to posterior, and inferior to superior.

Course: Skin, subcutaneous fat and muscle of left chest wall.

JOHN DOE NO. 4, aka DONALD DeFREEZE

Exit: Posterolateral aspect of left lower chest wall.

Projectile Recovery and Identification: Bullet jacket recovered. (Later identified as .223 caliber fired bullet jacket.)

DESCRIPTION OF GUNSHOT WOUNDS

There are two (2) gunshot wounds of the body. Pieces of both bullets are recovered. An incidental, old bullet is recovered from the right thigh.

Gunshot Wound No. 1, Head, Fatal

The entrance wound is located in the right temporal area 3 inches (7.6 cm) from the top of the head, 2 1/2 inches (6.4 cm) superior to the right external auditory meatus and 1/2 inch (1.3 cm) anterior to the external auditory meatus. The entrance wound, measuring 1 inch (2.5 cm) in greatest dimension, is irregularly circular in configuration, with charred borders, and is filled with coagulated brownish blood. The skin surrounding the entrance wound has largely been charred away, and there is charring of exposed muscles. Because of the subsequent charring, the presence or absence of powder residue within the wound and along the surrounding skin cannot be ascertained. The wound track passes through the head from right to left, from inferior to superior, at an angle of approximately 5 degrees, and from anterior to posterior at an angle of approximately 5 degrees. The track passes into the skull at about the junction of the temporal and parietal bones, producing a 3/8 inch (1.0 cm) hole with internal beveling. No definite powder residue is identified along either the wound in the bone or the underlying outer aspect of the dura.

From the entrance wound in the skull, a 6-inch (15-cm) irregular fracture extends posteriorly for about 1 1/2 inches (3.8 cm), and then continues posteriorly and superiorly to cross the midline of the posterior aspect of the calvarium. From a point on this fracture line, about 1 1/2 inches (3.8 cm) from the midline of the posterior aspect, an irregular, thin fracture line extends superiorly and anteriorly for a distance of 3 inches (7.6 cm) to end near the midline just forward of the vertex. The wound track through both cerebral hemispheres is ragged and hemorrhagic. The 3/8 inch (1.0 cm) irregularly-rounded exit wound in the left parietal bone has external beveling. The 1 inch (2.5 cm) irregularly-rounded exit wound of the scalp on the left side has charred borders. This exit wound is located directly above the external auditory meatus, 3 inches (7.6 cm)

JOHN DOE NO. 4, aka DONALD DeFREEZE

superior to the external auditory meatus, and 2 1/2 inches (6.4 cm) from the top of the head. Tiny fragments of brain tissue are found within the outer portions of this wound. Small, irregular metallic fragments, up to 1/8 inch (0.3 cm) in greatest dimension, are recovered from the entrance wound, the brain tissue, and the exit wound for further scientific studies.

Gunshot Wound No. 2, Left Chest Wall, Non-Fatal

The 1 inch (2.5 cm) irregularly-rounded entrance wound is located at the left posterior axillary line 23 inches (58.4 cm) from the top of the head. The entrance wound is partly filled by brownish, coagulated blood. The edges of the wound are somewhat charred. No definite powder can be identified within the wound or along the surrounding skin, which has brownish induration due to heat. The wound track passes into the body from left to right, at an angle of approximately 20 degrees from the sagittal plane, passing from inferior to superior, at an angle of approximately 35 degrees, and passing from anterior to posterior. The hemorrhagic irregular wound track passes through skin, subcutaneous fat and muscles to exit through a cutaneous wound measuring 1 1/8 inches (2.8 cm) in greatest transverse dimension, and 1 1/4 inches (3.1 cm) in greatest vertical dimension. No definite powder is found within or around this wound, which is located 22 1/2 inches (57.2 cm) from the top of the head, and 2 inches (5.1 cm) posterior to the entrance wound. Within the wound track, an irregular metallic fragment is found (later identified as a .223 caliber fired bullet jacket).

MICROSCOPIC DESCRIPTION OF GUNSHOT WOUNDS

Gunshot Wound No. 1, Head, Fatal

Sections of the entrance wound (Slides GSW No. 1 ENT) are present on three slides. One slide has two sections of remaining skin, skeletal muscle, and fascia. There is marked heat coagulation change throughout the tissue. Along the edge can be recognized residual skin appendage structures including hair shaft. Surface epithelium is incinerated. There is precipitated tissue fluid consistent with heat change separating skeletal muscle fragments. Along one edge of the wound track, there is extensive physical disruption of coagulated skeletal muscles, and identifiable powder residue material is embedded in this tissue. There is extravasation of preserved red blood cells along this edge. There are, additionally, more red blood cells identified in the depths of the tissue, including skeletal muscle and fascia.

JOHN DOE NO. 4, aka DONALD DeFREEZE

A second slide representing this wound includes sections of dura along the edge of the wound track. There is extensive disruption of the dura along one edge, and a few fragments of powder residue are seen along this edge. Also identified are minute pieces of human hair shafts embedded between torn dural fibers. There is coagulated blood and fibrin lining the inner surface of the dura, close to the edge of the site of disruption. In a cross section of the skull entrance wound, there are fragments of powder residue.

The exit wound (Slides GSW No. 1 EXIT) is present on three slides. Two of these slides have skin, subcutaneous fat, skeletal muscle and fascia. The skin has heat-induced coagulation of the epidermis extending to skeletal muscle with some swelling and ballooning of the subcutaneous fat. There are many residual scalp hairs remaining within follicles. There is prominent melanin pigmentation of the basal layer. Within the superficial epithelium are small bits of adherent carbonized material. No powder residue is identified. Along one edge, there is extensive disruption of the dermis, subcutaneous fat and muscle with extensive extravasation of blood into these tissues. On the third slide, portions of dura are disrupted along one margin, with mild heat coagulation effect and some precipitation of fibrin on the under-surface. No powder residue is seen.

Gunshot Wound No. 2, Left Chest Wall, Non-Fatal

The entrance wound (Slide GSW No. 2 ENT) has extensive heat coagulation change of the skin, subcutaneous fat and fascia. No epidermis is identified. Along one edge, there is considerable carbonaceous material embedded in the disrupted fat and fibrous tissue. No powder residue is found. Several laked red blood cells are seen along this edge. Fragments of synthetic fiber are also noted.

Sections of the exit wound (Slides GSW No. 2 EXIT) are found on two slides. The epidermis has extensive heat coagulation change which continues through the dermis and into the subcutaneous fat. Along one edge of the wound where synthetic fibers are embedded, there is extensive disruption of soft tissue and precipitation of tissue proteinaceous fluid. Red blood cells in this area appear laked. No powder residue is found.

GENERAL EXTERNAL DESCRIPTION

The unembalmed body is that of a well-developed and apparently well-nourished Negro male of light complexion, between 20 and 30 years of age, weighing 159 pounds (72.3 kg), and measuring 67 1/2 inches (171.5 cm) in length. There are

JOHN DOE NO. 4, aka DONALD DeFREEZE

extensive skin changes due to heat, involving all surfaces except the feet. Large portions of the skin of the face, head, left arm and right knee are absent, and there is charring of exposed muscles and bones. No vital reaction to the heat changes is identified. There is an oblique right lower quadrant abdominal surgical scar. No other scars are identified. No tattoos are found. Except for the gunshot wounds, no marks of antemortem trauma are identified. The skin of the external genitalia has minimal changes due to heat. The penis is uncircumcised.

Postmortem Skin Damage from Exploding Ammunition

Four metallic foreign bodies, noted by x-ray examination to lie over the left shoulder area, are found on dissection to be located along a 3-inch (7.6-cm) vertical line along the anterior aspect of the left deltoid muscle. The overlying skin and subcutaneous fat have been charred away. The fragments (later identified as one primer, two primer anvils, and one piece of brass from exploded shell casing) are of yellowish to brownish thin metal and measure up to 1/8 inch (0.3 cm) in greatest dimension. No vital reaction is found within the muscle tissue adjacent to the fragments.

Along the right side of the back, beginning 1 1/2 inches (3.8 cm) below the tip of the right shoulder, there is a 6-inch (15.2-cm) roughly vertical line of dark, ragged excoriations up to 1/8 inch (0.3 cm) deep and varying from 1/4 to 1 inch (0.6 to 2.5 cm) in greatest dimension. Adjacent to some of the lower marks there are irregular, tiny pits up to 1/16 inch (0.16 cm) in greatest dimension. The adjacent superficial skin, with heat changes, has peeled away. No vital reaction to any of these marks is identified.

Primary Incision

The body is opened with the usual Y-shaped incision.

Body Cavities

The pleural, peritoneal and pericardial surfaces are smooth and glistening. These cavities contain physiologic amounts of yellowish serous fluid.

Cardiovascular System

The heart weighs 320 grams and is of usual configuration. No dilatation of the heart chambers is noted and no hypertrophy of the muscular walls is seen. The valve leaflets are thin and pliable and no valve lesion is found. Endocardial surfaces are smooth and glistening. The myocardium

JOHN DOE NO. 4, aka DONALD DeFREEZE

is reddish-brown, firm and homogeneous. No focal myocardial lesions are found. The coronary arteries have no significant atherosclerosis. About 15 per cent of the intimal surface of the aorta has thin, yellowish atheromatous streaks and tiny atheromatous plaques.

Respiratory System

The right lung weighs 650 grams and the left lung, 620 grams. External surfaces have patchy, red discoloration. On sectioning, the lungs are moderately congested and edematous. The principal bronchi are clear of foreign material and the mucosa is pink. There is dark reddening of the mucosa of the larynx and pharynx without swelling or obstruction of the airway. Ashes and soot are present only in the mouth area. The pulmonary vessels are free of emboli.

Hemolymphatic System

Intravascular blood is dark red and clotted. The 110-gram spleen is of usual color and configuration. No enlarged lymph nodes are seen. The thymus is atrophic, consistent with age.

Digestive System

The esophagus is of usual size and configuration. The esophageal mucosa is pink. The stomach contains about 20 ml of partly digested, unidentified food material. No residuals of medication are seen. The mucosa is not inflamed. No lesion of the small or large intestines is noted. The appendix is absent.

Hepatobiliary System

The liver weighs 1100 grams. The external surfaces are smooth and the edges are sharp. Cut surfaces have the usual reddish-brown color and no fibrosis is evident. The gallbladder and the extrahepatic biliary ducts are of usual configuration and no lesion is seen.

Urogenital System

The kidneys are of usual configuration and each kidney weighs 165 grams. The capsules are readily stripped from smooth grey-brown cortical surfaces. On sectioning, no focal lesions of the parenchyma are noted. The pelvis, ureters and urinary bladder are of usual configuration and no abnormality is seen. The bladder contains clear urine. No lesion of the testes is noted. The penis is uncircumcised.

JOHN DOE NO. 4, aka DONALD DeFREEZE

Musculoskeletal System

A bullet is found encased in fibrous tissue, adjacent to the inner aspect of the proximal third of the shaft of the femur. No wound track is found. No damage to major vessels and nerves is apparent. Due to heat damage of skin of the area, the entrance wound scar is not identified. Bullet is jacketed with a darkened external surface (later identified as a .32 caliber automatic pistol bullet). The bones and muscles encountered in the performance of the autopsy have no distinct lesion except as previously mentioned.

Endocrine System

The adrenal and thyroid glands are of usual size, color and consistency. No abnormalities of the pancreas are found.

Head and Central Nervous System

On reflection of the scalp, no trauma except for that noted under Gunshot Wounds is found. Associated with charring of the anterior frontal scalp and skull, there is a thin layer of light brownish-red coagulated blood in the epidural space. The sectioned 1200-gram brain is sent to the Forensic Neuropathologist for further study.

GENERAL MICROSCOPIC DESCRIPTION

Heart (Slides No. 15-6,9)

Two sections of myocardium have moderate engorgement of the myocardial vascular bed. There is extremely minimal perivascular fibrosis near the base of the septum. In one section (No. 15-9), a portion of the conduction system is identified and is unremarkable. The endocardium is unremarkable. The branches of the coronary artery tree have no significant microscopic alterations.

Aorta (Slide No. 15-8)

A longitudinal section of aorta has multiple fibrolipid intimal atherosclerotic plaques. Many foam cells are identified within the plaques. No plaques are seen in the tributaries branching off the aortic section. The periaortic fatty tissue is of the fetal type, having a coarsely vacuolated cytoplasm.

JOHN DOE NO. 4, aka DONALD DeFREEZE

Lungs (Slides No. 15-1,5)

Slide No. 15-1 has a normal pleura with some small aggregates of anthracotic pigment in the immediate subpleural tissues. There is a large amount of edema fluid manifested by pink-staining proteinaceous material within most of the alveolar spaces. The vascular bed of the lung is intensely congested with red blood cells. In one alveolar duct, there is a small bacterial colony surrounding a fragment of carbonaceous material. No foreign body granulomata are identified in the alveolar septa.

The section on Slide No. 15-5 has considerably less edema fluid in alveolar spaces and better aeration of the alveoli. There are, however, increased numbers of pulmonary histiocytes in the alveoli and there is intense congestion of the capillary bed. Scattered perivascular and peribronchiolar lymphocytic aggregates are seen. There are no granulomata. Small aggregates of anthracotic pigmentation are also seen in the subpleural connective tissue. In some of the smaller vascular channels there are sequestered neutrophilic leukocytes.

Trachea (Slide No. 15-4)

The tracheal cartilage has no evidence of calcification. There is almost complete denudation of the surface epithelium, so that only a few basal cell elements are identified on the basement membranes. There is intense engorgement of the capillary bed and vascular plexus of the tracheal wall. Many of the most engorged vessels are noted in the subepithelial tissues. There is spotty chronic inflammation in many of the tracheal glands. The orifices of some tracheal glands contain thick mucus. In this mucus can be identified occasional bacteria.

Spleen (Slide No. 15-14)

The spleen has prominent white pulp follicles with little reticuloendothelial activity.

Tonsils (Slide No. 15-10)

Tonsillar tissue has prominent lymphoid follicles and deep crypts containing abundant cellular debris. Peritonsillar connective tissue and skeletal muscle tags have mild fibrosis consistent with old tonsillitis.

Liver (Slide No. 15-11)

The general architecture of the liver is preserved. A rare

JOHN DOE NO. 4, aka DONALD DeFREEZE

liver cell contains fatty vacuoles, and there is moderate lipochrome pigmentation of many of the liver cells. The portal triads are free of significant inflammatory infiltrate. The entire vascular bed of the liver appears intensely congested. No sickled cells are found.

Kidneys (Slides No. 15-11,14)

The kidneys have an essentially normal architecture. There is some autolytic change involving the cortical tubules out to the capsule. The glomeruli have essentially normal structure. There is moderate congestion of the medullary capillary network. In one section (No. 15-14), there is a small capsular scar with hyalinized glomeruli and fibrotic tubules surrounded by a few lymphocytes.

Prostate (Slide No. 15-2)

Glandular elements of prostatic tissue have some autolytic change. There are occasional corpora amylacea within prostatic glandular acini. There is no evidence of inflammatory disease.

Testes (Slides No. 15-3,7,12)

Portions of epididymis have postmortem sloughing of some of the lining epithelium. The epididymal tubules contain moderate numbers of spermatozoa and there is no evidence of active inflammatory disease or scarring. The periepididymal vessels have moderate engorgement. The testicular tubules have slightly decreased spermatogenesis for the age of the individual, but maturation through spermatozoa is seen in most of the tubules. There appears to be mild thickening of the peritubular connective tissue. The interstitial cells appear normal in number and pattern. The testicular tunic tissue is unremarkable.

Adrenal (Slide No. 15-12)

The adrenal has well-preserved parenchyma with engorgement of the periadrenal vessels. The cortex appears slightly nodular without true adenoma formation. The cells of the zona glomerulosa have abundant lipid vacuoles.

Dura (Slide No. 15-15)

Strips of dura have a small amount of adherent coagulated blood on one surface. Within this blood are some bacterial colonies. No other changes are recognized.

FORENSIC NEUROPATHOLOGY EXAMINATION

Gross Findings

Two fragments of dura are submitted. The first fragment consists of dorsolateral portions somewhat in the shape of an inverted "T". The measurement along the superior sagittal sinus is 13 cm. On the right side of the superior sagittal sinus anteriorly it measures 2.8 cm in width for a distance of 5 cm. More posteriorly it is somewhat triangular, measuring from 5 cm anteriorly to 9 cm posteriorly in a transverse measurement. On the left side, the anterior portion measures 0.5 to 5 cm in width from the midline and more posteriorly the fragment measures 9.5 cm. On the epidural surface of the left frontal region, there is some epidural blood clot up to 1 mm in thickness covering an area about 5 cm in diameter. The blood has a brown clay-like appearance. Similar altered blood is present on the right epidural surface in the corresponding region. The more posterior portions of the epidural surface are free of such blood. The subdural surfaces, both left and right, have a small amount of similar coagulated blood which, on the left side, is spotty and less than 1 mm in thickness. On the right in the anterior aspect of the wider portions, there is a triangular patch about 2 cm in diameter by 2 to 2.5 mm in thickness which is quite adherent to the dura. It appears that the lateral portions of the anterior aspect of the dura have been selectively removed as shown by the multiple scissor-cut edges. Thus this fragment of dura does not contain any pathologic defect. The dural sinus contains no antemortem thrombus.

The second fragment of dura consists of the occipital portions, the portion from the posterior fossa, and the right middle fossa. In the right middle fossa and the left posterior fossa, there is some black colored, adherent blood which is very much altered and cannot be removed. This is less than 1 mm in thickness. Most of the remainder of the dura has no blood on the subdural surfaces. There is a large amount of coagulated blood, some of which appears almost charred on the external surfaces of the right middle fossa and temporal region. This entire portion of dura is partly dried.

Seven previous, essentially coronal cuts have been made at even intervals through the cerebrum. There is considerable distortion of the specimen due to previous sectioning and fixation. There is some subarachnoid hemorrhage on the dorsal and medial aspects of the right frontal lobe, but more on the medial where the convolutions are obscured by the blood. The subarachnoid space in general has diffuse

JOHN DOE NO. 4, aka DONALD DeFREEZE

blood staining more in the frontal regions and the right temporal region without actual blood clot. The blood clot on the medial surface of the right side extends posteriorly to the precuneus. The left side has only blood staining on the medial surface along the sulci.

There is a track-like defect extending from the right side at a point just above the lateral fissure and 5 to 6 cm posterior to the frontal pole, extending through the cortex, white matter and the striatum beneath the fornix through the left cerebral hemisphere in a somewhat symmetrical fashion, although slightly more superiorly located on the left side. There has been previous dissection along the external surface of the left cerebral hemisphere, so that the exact location of the external opening on the left side cannot be visualized. The track appears to be about 1 to 2 cm in diameter in the more recognizable portions. This track has ragged hemorrhagic surfaces with some petechiae surrounding the track, especially in the body of the fornix. The columns of the fornix have been destroyed. The ventricular wall is blood stained, but there is no blood clot at present.

In the right striatum there are petechial hemorrhages ranging from 1 to 3 mm in size, spaced several millimeters apart throughout the entire structure. On the left side, the hemorrhages are confined to areas along the track.

Along the track in the left striatum, a 5 x 4 x 1 mm irregular fragment of grayish, shiny metal is found (retained for study). In the cerebral cortex in the areas surrounding the external defect of the right cerebral hemisphere, there are intracortical contusions at a distance 2 to 3 cm from the external wound. Similar intracortical contusions are present in the left cerebral hemisphere about 3 to 4 cm from the exit wound area. In areas more distant from the track, no vascular abnormalities, tumors or other lesions are found.

The cerebral convolutions in general are flattened. The cortex has a darker gray color than usual. The ventricles and sulci are markedly narrowed. The cortex of the right parahippocampal gyrus has minute petechiae within its substance. There is no surface defect. The hippocampi and right amygdala are normal in size and color. There is no evidence of sclerosis or other gross lesion. The adjacent inferior horn is markedly narrowed. The left amygdala cannot be identified. Both cingulate gyri have no apparent lesions. There is no cingulate herniation on either side. Horizontal sections through the upper pons have marked congestion in the tegmental portion along the midline. The medulla has no lesion. The cerebellar tonsils are markedly herniated.

The spinal cord, which is enclosed in dura mater, measures 32 cm in length. The upper end is at a level 4 mm above C₁, while the lower end is at L₂. The epidural surface has a gray color. There is a small amount of lipoareolar tissue and no hemorrhage. The subdural surface has diffuse brownish-red blood stain. The arachnoid is thin. There is subarachnoid hemorrhage, more in the lower two-thirds of the thoracic segment and the lumbar region, where the blood is up to 1 mm in thickness surrounding the entire circumference of the cord. The spinal cord is moderately swollen. The cut surfaces on transverse sections at all levels have a light yellow color. The normal configuration of the gray and white matter is rather indistinct. The nerve roots are grossly intact. Six posterior root ganglia are present on the right side between C₁ and C₆, and six ganglia between left C₁ and C₄. These ganglia are of normal size and appearance.

Microscopic Description

There is generalized congestion, extravasation and some homogenization of the blood in the lumina of the blood vessels. The endothelial cells are swollen. In the cerebral cortex there is acute swelling of the nerve cell nuclei. There are lightly-stained nucleoli with indistinct chromatin material and nuclear membranes. The Nissl bodies are mostly lysed. The cytoplasm is homogenized, some of it quite indistinct, merging into the homogenized, some of it quite indistinct, merging into the homogenized matrix. The basal ganglia have better preserved nerve cells, although some changes are similar to that of the cortex. There is swelling of the glial nuclei in the white matter.

Sections taken along the cerebral missile track have embedded bone spicules in the vicinity of the ventricle. No powder residue is identified along the track.

Multiple sections of the amygdala and hippocampus have no sclerosis or other lesion. Petechiae are present in the cerebral cortex surrounding the defects, and in the parahippocampal gyrus.

In the brain stem and spinal cord, there is better preservation of the nerve cells. The fiber tracts of the spinal cord are swollen and granular. The anterior horn cells have occasional central chromatolysis. The remainder of the cells are quite well-preserved. The subdural and subarachnoid blood of the spinal cord has partial hemolysis. The cerebellum has much better preservation of the general architecture. However, the Purkinje cells are swollen and homogenized with indistinct red-staining nucleoli. The cytoplasm is eosinophilic. There are red blood cells on the ventricular wall. These red blood cells are quite well-preserved.

JOHN DOE NO. 4, aka DONALD DeFREEZE

Diagnoses

1. Gunshot wound track of cerebrum, through and through, with associated cerebral contusions.
2. Brain and spinal cord with postmortem heat-induced changes.

FORENSIC RADIOLOGY EXAMINATION

Varying-sized metallic fragments are stuck to the burned surfaces of the skin and silvery-grey droplets of previously molten metal are found along various portions of the body surfaces. Radiographs are taken with such fragments on the body.

Thorax and Abdomen

Ten films, covering the thorax and abdomen, excluding the pelvis, taken on 5-18-74 and during a confirmatory examination on 5-20-74, document multiple, minute soft tissue metallic fragments. Along the left lower aspect of the thoracic wall projected over the level of the fifth rib, there is an irregularly-shaped, thin metallic fragment measuring in the x-ray projection approximately 1/2 x 1/4 inch (1.3 x 0.6 cm) in greatest dimension. A similar fragment is projected over the right axillary area and lateral aspect of the chest on the right. There are several soft tissue metallic fragments seen in the left axilla, including a metallic primer. An irregular thin metallic fragment is noted along the lower aspect of the left side of the chest. The visualized bony elements have no evidence of trauma.

Skull

A single AP view has areas of discontinuity in both temporal areas, consistent with entrance and exit wounds. Projected over the upper calvarial area and through the orbits are multiple metallic fragments. A single specimen view of the removed brain has over fifty (50) tiny metallic fragments ranging from barely visible to 1/4 x 1/8 inch (0.6 x 0.3 cm) as viewed on the film.

Specimen radiographs of the calvarium, dura and brain are noted.

Extremities

Twelve views of the extremities are examined. An ovoid dense metallic object measuring 7/16 x 3/8 inch (1.2 x 1.0 cm) on the film is noted in the upper inner soft tissue of the

JOHN DOE NO. 4, aka DONALD DeFREEZE

right thigh adjacent to the middle of the proximal third of the diaphysis of the right femur. A 3/16 inch (0.5 cm) thin metallic fragment is found in the area adjacent to the junction of the middle and distal thirds of the right femoral diaphysis. The remainder of the examination of the lower extremities is unremarkable except for metallic fragments projected over the left obturator foramen and ischium. Two fragments project in the soft tissues overlying the proximal left femur.

The left arm has multiple, superficial soft tissue densities including metallic fragments and a primer. Some of these fragments are seen overlying the left hand and the soft tissues of the lateral aspect of the lower portion of the left hemithorax. None of these views has evidence of fracture or dislocation.

FORENSIC ODONTOLOGY EXAMINATION

The maxilla and mandible of John Doe No. 4, Case No. 74-6764, are examined. Occlusion is Class I in the cuspid areas, but drifting has occurred in the buccal segments due to loss of all four first molars and the mandibular left second molar. Four amalgam restorations are present.

The maxilla, mandible, and postmortem radiographs are compared to two outpatient dental cards from the Southern Reception Center, Chino, California, describing dental treatment rendered to Donald D. DeFreeze, Reg. No. B-24833. The postmortem radiographs consist of fourteen periapical films and two bite-wing films. The most recent chart entry is 8-10-72, and the earliest is 1-5-70. Antemortem radiographs are not available, although the charts indicate radiographs were taken 6-1-71 and 11-15-71.

The dental charts describe all four of the fillings found in the jaws of John Doe No. 4, both as to teeth and surfaces involved. In addition, the charts describe the removal of the remains of Tooth No. 3, which is also missing in the case of John Doe No. 4. The charts also describe the absence of Teeth No. 14, No. 18, No. 19 and No. 30. These teeth are also missing in the case of John Doe No. 4.

Conclusion

Based solely on the dental evidence, there is an extremely high probability that John Doe No. 4 is the same individual described on the dental charts labelled "Donald DeFreeze." Although the antemortem radiographs would be expected to finalize the identification, the combination of matching

JOHN DOE NO. 4, aka DONALD DeFREEZE

extraction patterns and matching filling patterns makes the probability of such a similarity occurring by chance very small. Identification, in this case, is confirmed by fingerprint evidence.

FORENSIC TOXICOLOGY EXAMINATION

| <u>Specimen</u> | <u>Compound</u> | <u>Result</u> |
|-----------------|--|---------------|
| <u>Blood</u> | Amphetamines | Neg. |
| | Carbon Monoxide (CO) saturation | 17% |
| | Ethanol, Barbiturates, and Neutral Drugs | Neg. |
| | Morphine, Codeine and Cocaine | Neg. |
| | Salicylates, Trichlorethanol, Ethchlorvynol, Basic Drugs, Diphenhydramine and Oxazepam | Neg. |
| | "Tear Gas" (i.e., Chloroacetophenone (CN) and O-chlorobenzalmalonitrile (CS) | Neg. |
| | Gasoline | Neg. |
| | Cyanide determination | Neg. |
| <u>Lung</u> | "Tear Gas" (i.e., Chloroacetophenone (CN) and O-chlorobenzalmalonitrile (CS) | Neg. |
| <u>Liver</u> | Barbiturates and Neutral Drugs | Neg. |
| | Phenothiazines and Basic Drugs | Neg. |

FORENSIC BIOLOGY EXAMINATION

Material Submitted

Blood for Typing

Findings

Type: O
Rh: Positive

COUNTY OF LOS ANGELES

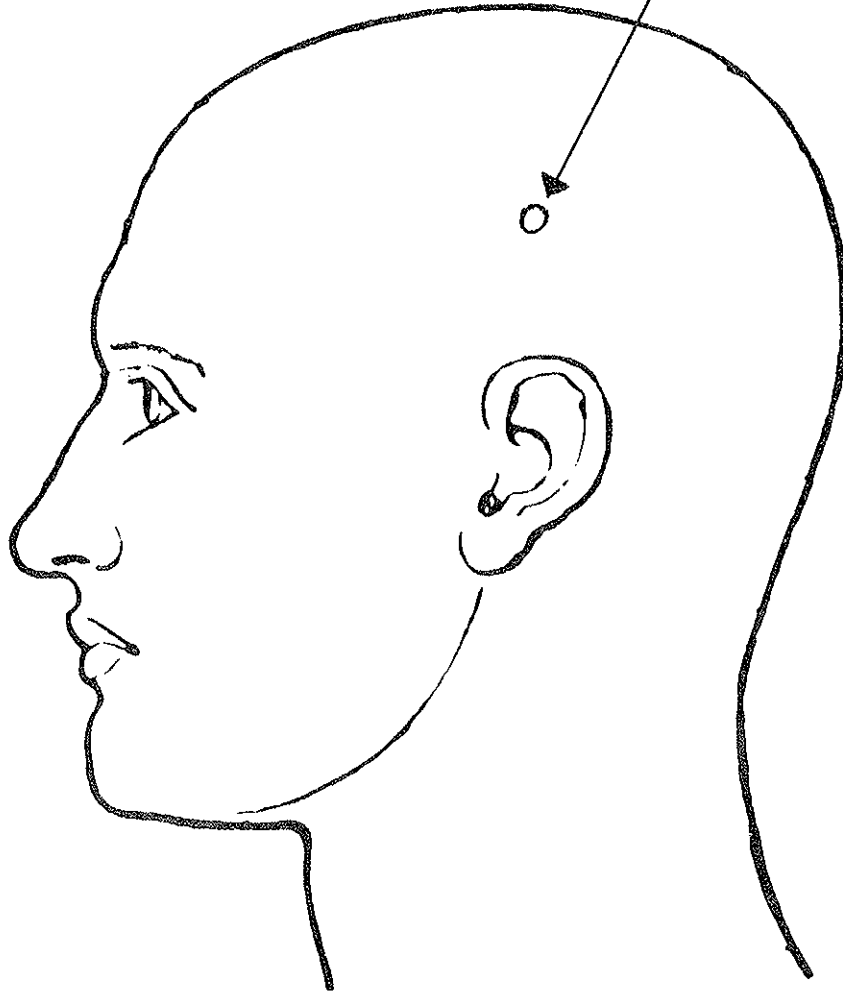
OFFICE OF CHIEF MEDICAL EXAMINER-CORONER

HEAD - LATERAL LEFT

NAME JOHN DOE NO. 4, aka DONALD DeFREEZE Date May 18, 1974 File # 74-6764

GUNSHOT WOUND NO. 1

- 1" Exit Wound
- 2 1/2" From Top of Head
- 3" Directly Above External Auditory Meatus



LEFT

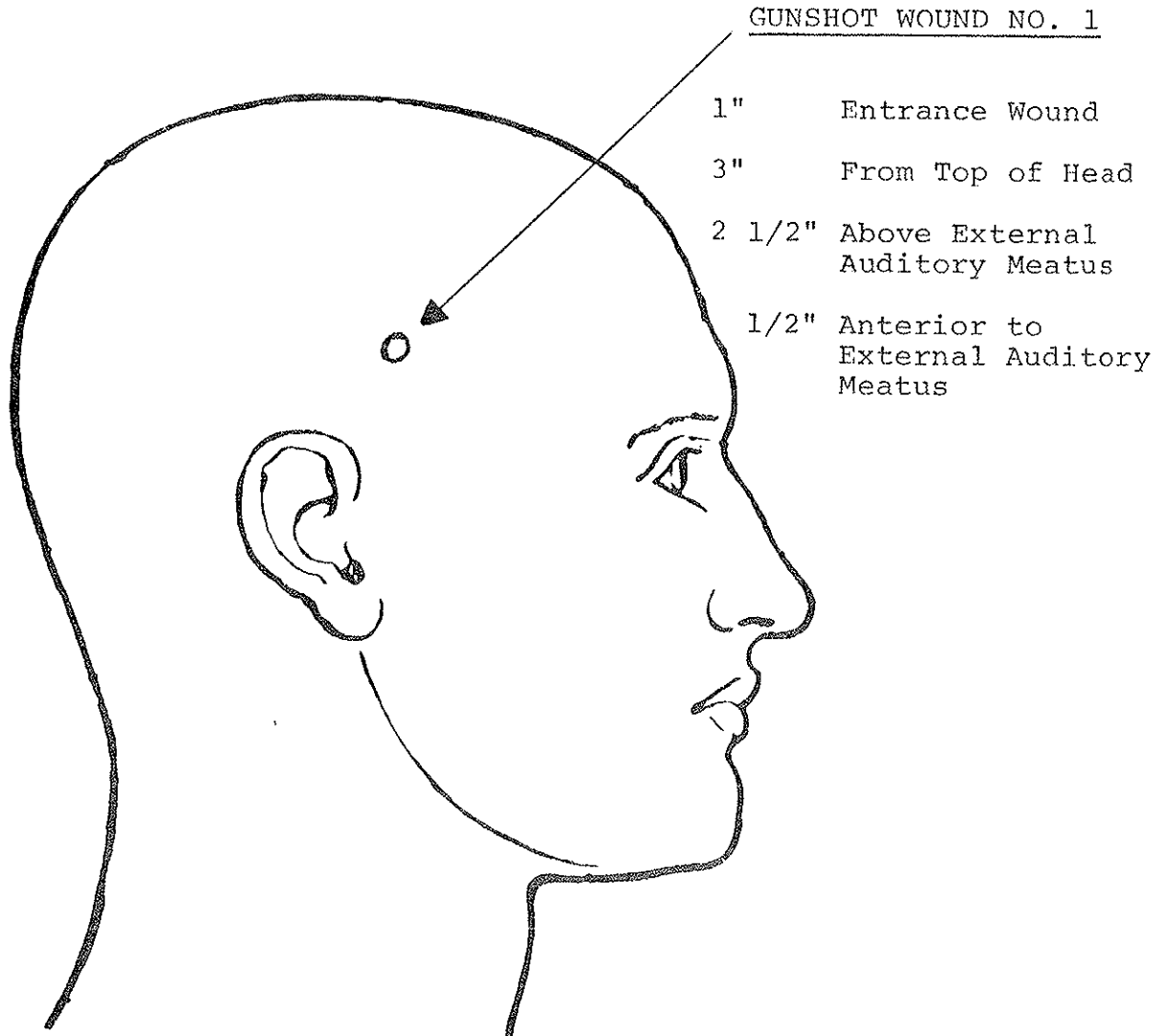
COUNTY OF LOS ANGELES

OFFICE OF CORONER

NAME JOHN DOE NO. 4, aka DONALD DeFREEZE

Date May 18, 1974

File # 74-6764



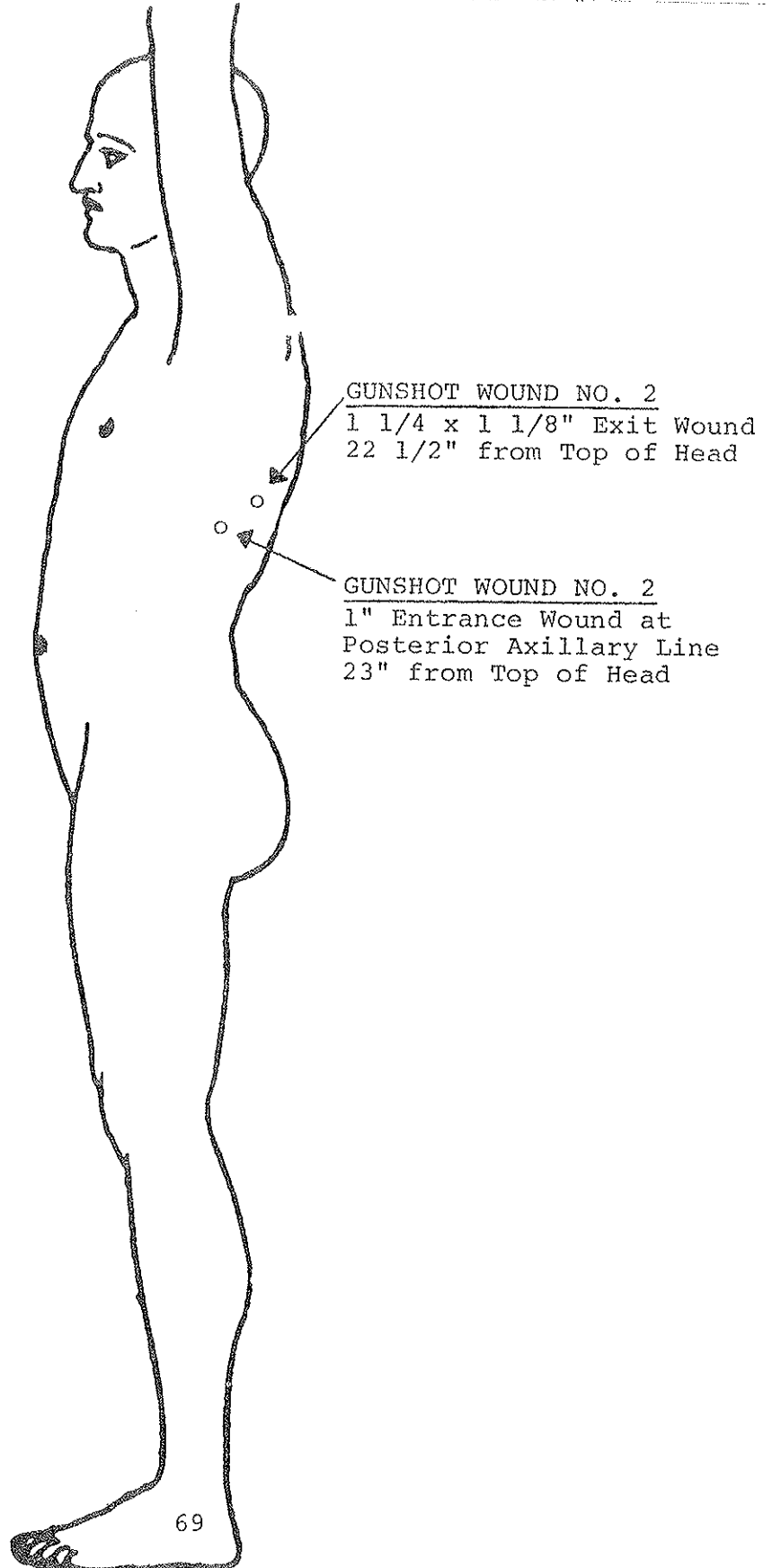
COUNTY OF LOS ANGELES

OFFICE OF CORONER

NAME JOHN DOE NO. 4, aka DONALD DeFREEZE

Date May 18, 1974

File # 74-6764



LEFT

1974 - Cdb 4-57

Autopsy Surgeon

COUNTY OF LOS ANGELES
DEPARTMENT OF CHIEF MEDICAL EXAMINER - CORONER

NAME John Doe No. 4, aka DONALD DE FREEZE

Date May 18, 1974

File No. 74-6764

| | UPPER RIGHT | UPPER LEFT | LOWER RIGHT | LOWER LEFT | | | | | | | | | | | | |
|--|-------------|------------|-------------|------------|----|----|----|----|----|----|----|----|----|----|----|----|
| | 1 | 2 | 3 | 4 | 5 | 6 | 7 | 8 | 9 | 10 | 11 | 12 | 13 | 14 | 15 | 16 |
| Slight infra-occlusion, otherwise normal | | | | | | | | | | | | | | | | |
| Distal pit caries | | | | | | | | | | | | | | | | |
| Missing--virtually no space closure | | | | | | | | | | | | | | | | |
| Normal with very little separation of contact | | | | | | | | | | | | | | | | |
| Normal--slightly charred | | | | | | | | | | | | | | | | |
| Crown badly charred--no evidence of prior pathology | | | | | | | | | | | | | | | | |
| Charred to the crest of the alveolar bone; | | | | | | | | | | | | | | | | |
| Roots present. | | | | | | | | | | | | | | | | |
| Normal; slightly charred | | | | | | | | | | | | | | | | |
| Normal except for slight spacing | | | | | | | | | | | | | | | | |
| Missing--space closed approximately one-third | | | | | | | | | | | | | | | | |
| D0 amalgam restoration | | | | | | | | | | | | | | | | |
| Occ. amalgam restoration slight infra occlusion | | | | | | | | | | | | | | | | |
| | 32 | 31 | 30 | 29 | 28 | 27 | 26 | 25 | 24 | 23 | 22 | 21 | 20 | 19 | 18 | 17 |
| Occ. Amalgam restoration; small pit cavity on DB portion of occ. | | | | | | | | | | | | | | | | |
| D0 amalgam restoration | | | | | | | | | | | | | | | | |
| Missing with not more than 25% space closure | | | | | | | | | | | | | | | | |
| Normal, virtually no separation | | | | | | | | | | | | | | | | |
| Normal, slightly charred | | | | | | | | | | | | | | | | |
| Charred to the crest of the alveolar bone; roots present | | | | | | | | | | | | | | | | |
| Normal, slightly charred | | | | | | | | | | | | | | | | |
| Normal | | | | | | | | | | | | | | | | |
| Missing | | | | | | | | | | | | | | | | |
| Marked mesial tipping and drifting | | | | | | | | | | | | | | | | |

LEGEND:

Amalgam: A; Gold: G; Silicate: S;
Acrylic: Ac; Missing Teeth: X

JOHN DOE NO. 4, aka DONALD DeFREEZE

REPORT OF AT-SCENE AND FOLLOW-UP INVESTIGATION

Doe No. 4, later identified as John Doe No. 4, aka Donald DeFreeze, was found lying partially on his right (R) side between Doe No. 3 and Doe No. 5, head facing to the south, at the southeast corner of the burned structure near the air vent in the foundation. The body is extensively charred. A search of the area around and under the body made by the Coroner's Senior Investigator and Coroner's Photographer revealed two wrist watches on the ground close to the wrist of the deceased. Also found under the body was what appeared to be a .38 caliber, snub-nose revolver which was taken at that time by the Investigating Officer of the Los Angeles Police Department.

The decedent was brought to the Forensic Science on May 17, 1974 at 2305 hours by the Coroner's Senior Investigator and Investigator.

Physical Description

Male Negro; between 20 and 30 years of age; charred
Weight: 159 pounds
Height: 67 1/2 inches

Clothing on Body

The articles of burned clothing were inventoried and released to the Scientific Investigation Division of the Los Angeles Police Department at 1610 hours on May 18, 1974.

Personal Property Found on and Under
Body and in Remnants of Clothing

The articles of personal property were inventoried and released to the Scientific Investigation Division of the Los Angeles Police Department on May 18, 1974 at 1600 hours, with the exception of \$0.36 in coin, which is retained in the Coroner's custody until completion of the investigation.

Additional Evidence Found on Body

Additional evidence was found on the body by the Coroner's Medical Photographer on May 18, 1974 between the hours of 0125 and 0215, while photographing the body at the Forensic Science Center. The evidence was inventoried and later released to the Scientific Investigation Division of the Los Angeles Police Department on May 20, 1974 at 1430 hours.

COUNTY OF LOS ANGELES
DEPARTMENT OF CHIEF MEDICAL EXAMINER-CORONER
LOS ANGELES, CALIFORNIA 90033

JANE DOE NO. 5, aka PATRICIA SOLTYSIK

Case No. 74-6765

This is to certify that the autopsy on the body of Patricia Soltysik was performed at The Forensic Science Center, Los Angeles, by the staff of the Department of Chief Medical Examiner-Coroner, on May 18, 1974.

CAUSE OF DEATH: EXTENSIVE BURNS, SMOKE INHALATION
AND GUNSHOT WOUNDS

The detailed medical findings, opinions and conclusions required by Section 27491 of the Government Code of California are attached.

Thomas T. Noguchi, M.D.
Chief Medical Examiner-Coroner

ANATOMICAL SUMMARY

GUNSHOT WOUNDS

1. Gunshot wound of right upper arm, non-fatal.
2. Gunshot wound of right upper back, non-fatal.
3. Gunshot wound of right upper back, non-fatal.
4. Gunshot wound of right lower thigh, non-fatal.

OTHER PERTINENT FINDINGS

1. Cutaneous thermal burns.
2. Thermal burns of laryngeal and bronchial mucosa.
3. Pulmonary congestion and edema.

POSTMORTEM CHANGES

1. Postmortem charring of body.
2. Postmortem damage from exploding ammunition.

SUMMARY OF GUNSHOT WOUNDS

Gunshot Wound No. 1, Right Upper Arm, Non-Fatal

Entry: Unknown, due to extensive burns.
Direction: Undetermined.
Course: Jacket material located in hemorrhagic area of right biceps muscle.
Exit: None.
Projectile Recovery and Identification: .223 caliber bullet jacket.

Gunshot Wound No. 2, Right Upper Back, Non-Fatal

Entry: Right upper back.
Direction: Slightly left to right, slightly posterior to anterior, superior to inferior.
Course: Skin, subcutaneous tissue and muscles of back.
Exit: None.
Projectile Recovery and Identification: #00 buckshot.

JANE DOE NO. 5, aka PATRICIA SOLTYSIK

Gunshot Wound No. 3, Right Upper Back, Non-Fatal

Entry: Right upper back.

Direction: Slightly left to right, slightly posterior to anterior, superior to inferior.

Course: Skin, subcutaneous tissue and muscles of back.

Exit: None.

Projectile Recovery and Identification: #00 buckshot.

Note: The tracks of Gunshot Wounds No. 2 and No. 3 are essentially parallel.

Gunshot Wound No. 4, Right Lower Thigh, Non-Fatal

Entry: Unknown, due to extensive burns.

Direction: Undetermined.

Course: Fragments located in hemorrhagic muscles.

Exit: None.

Projectile Recovery and Identification: Two (2) pieces of .223 caliber bullet jacket.

DESCRIPTION OF GUNSHOT WOUNDS

Gunshot Wound No. 1, Right Upper Arm, Non-Fatal

A thin, metallic fragment (later identified as a piece of .223 caliber bullet jacket), located by x-ray examination, is found within a hemorrhagic area of the lower right biceps muscle, about 2 inches (5.1 cm) above the right antecubital fossa. The skin of this portion of the arm has been burned away, so that no entrance wound in the skin can be identified. The biceps muscle is also partly charred. Because there is no distinct track, no estimation of the direction and course of this fragment can be made.

Gunshot Wound No. 2, Right Upper Back, Non-Fatal

The entrance wound is located 15 inches (38.1 cm) from the

JANE DOE NO. 5, aka PATRICIA SOLTYSIK

top of the head, and 1/2 inch (1.3 cm) to the right of the midline of the back. There are extensive heat-induced changes, including some charring of the skin surrounding this entrance wound, so that no powder marks, if present, can be identified. The entrance wound is ovoid in shape, measuring 1/4 x 3/8 inch (0.6 x 1.0 cm) in greatest dimensions. The wound track measures approximately 5 inches (12.7 cm) in length. This track passes from left to right at an angle of about 10 degrees away from the center line of the back, very slightly posterior to anterior, and from superior to inferior. The hemorrhagic track passes through subcutaneous tissue and the superficial portions of the muscles of the back. At the distal end of the track, there is found a lead pellet (later identified as #00 buckshot).

Gunshot Wound No. 3, Right Upper Back, Non-Fatal

The entrance wound is located 17 inches (43.2 cm) from the top of the head, and 1 1/2 inches (3.8 cm) to the right of the midline of the back. The entrance wound is ovoid, measuring 1/4 x 3/8 inch (0.6 x 1.0 cm). There is heat-induced brownish induration of surrounding skin, so that powder marks, if present, are not identifiable. The wound track is approximately 5 inches (12.7 cm) in length. The track passes from left to right, at an angle of about 10 degrees from the midline of the back. It passes slightly from posterior to anterior, and passes from superior to inferior. The hemorrhagic track passes through skin, subcutaneous tissue and superficial portions of the muscles of the back. At the distal end of the track, there is found a lead pellet (later identified as #00 buckshot).

Note: The tracks of Gunshot Wound No. 2 and Gunshot Wound No. 3 are essentially parallel.

Gunshot Wound No. 4, Right Lower Thigh, Non-Fatal

Two thin, metallic fragments (later identified as pieces of .223 caliber bullet jackets), located by x-ray examination, are found within hemorrhagic muscle tissue of the anterior portion of the lower right thigh, 3 to 4 inches (7.2 to 10.2 cm) above the right knee. The overlying skin has been burned away and there is charring of the outer portion of the muscles in this area, so that no entrance wound is identified. No distinct wound tracks can be identified in hemorrhagic muscle, so that direction and course of the fragments cannot be established.

JANE DOE NO. 5, aka PATRICIA SOLTYSIK

MICROSCOPIC DESCRIPTION OF GUNSHOT WOUNDS

Gunshot Wound No. 1, Right Upper Arm, Non-Fatal

No microscopic studies (no identifiable entrance wound).

Gunshot Wound No. 2, Right Upper Back, Non-Fatal

Tissue from the margin of the entrance wound (Slide GSW No. 2) has extensive heat-induced coagulation changes. There is loss of much of the epidermis, with some embedded carbonaceous debris. No powder residue is identified. In deeper tissues, there are interstitial extravascular laked red blood cells.

Gunshot Wound No. 3, Right Upper Back, Non-Fatal

Two slides of the tissue along the margin of the entrance wound (Slides GSW No. 3) are studied. There are extensive heat-induced coagulation changes of the tissue. Much of the epidermis has been lost. There are particles of carbonaceous debris along the surfaces. No powder residue is identified. Within deeper tissues, there are extravascular laked red blood cells.

Gunshot Wound No. 4, Right Lower Thigh, Non-Fatal

No microscopic study (no identifiable entrance wound).

POSTMORTEM DAMAGE FROM EXPLODING AMMUNITION

Embedded superficially within the anterior aspect of the mid portion of the right biceps muscle, there are three metallic objects (later identified as a 9 mm exploded shell casing, an ammunition primer, and an unfired 9 mm hollow-point bullet). There is no vital reaction in this area. The overlying skin has been burned away.

Along the anterolateral aspect of the mid and upper abdomen, on the right, there are two irregular openings in the skin up to 1/4 inch (0.6 cm) in dimension with no vital reaction and no surrounding powder marks. In the subcutaneous areas there are two thin, irregular metallic fragments (later identified as pieces of shell casing). There is no reaction in the subcutaneous tissues.

Embedded in charred muscles of the anterolateral aspect of the right upper and mid thigh, there are three metallic fragments (later identified as two ammunition primers and one primer anvil). There is no vital reaction in these areas.

JANE DOE NO. 5, aka PATRICIA SOLTYSIK

Along the inner aspect of the anterior portion of the forearm, about 3 inches (7.6 cm) above the wrist, there is an irregular hole about 1/2 inch (1.3 cm) in greatest dimension, with an underlying track extending anterior to posterior, and from inferior to superior, approximately parallel to the sagittal plane. At the distal end of this track, there is found a partly deformed bullet and a partly deformed jacket (later identified as an unfired .38 special, jacketed, hollow-point bullet). Margins of the track are somewhat hemorrhagic.

GENERAL EXTERNAL DESCRIPTION

The unembalmed body is that of a well-developed and apparently well-nourished white female of 20 to 30 years of age, weighing 123 pounds (55.9 kg), and measuring 63 inches (160 cm) in length in the present condition. There are extensive skin changes due to heat. In places there is loss of skin with charring of underlying fat, bone and muscular tissue. The charring involves particularly the entire head and the upper shoulders, the right arm and hand, and a portion of the right lateral chest wall. Charring involves almost the entire right thigh and hip area, and similar changes are noted along the upper portion of the right lower leg. There is loss of upper skin layers over the left lower leg and knee area with extensive reddening of the underlying tissue. Reddening of the skin is also noted adjacent to burns along the lower abdomen. There is some sparing of skin along the upper portion of the abdomen and feet. Remaining skin is dark brown to black and indurated.

The extremities are fixed in slight flexion except for the left arm, the upper portion of which is abducted and the lower portion of which is flexed across the upper portion of the chest, anteriorly. The scalp hair has been burned away. The pubic, axillary and leg hair is light brown in color. There is a 2 1/4 inches (5.7 cm) horizontal surgical scar in the right lower quadrant of the abdomen. No abnormalities of the external genitalia or anus are noted. No tattoos are found. There are no old or recent needle marks on the left arm. No breast lesion is noted.

Primary Incision

The body is opened with the usual Y-shaped incision.

Body Cavities

The pleural, peritoneal and pericardial cavities are noted to be lined with smooth, glistening membranes. There are

JANE DOE NO. 5, aka PATRICIA SOLTYSIK

physiologic amounts of fluid within these cavities.

Cardiovascular System

The 320 gram heart is of usual configuration. There is no dilatation of the chambers, or hypertrophy of the muscular walls. The myocardium is reddish-brown, firm and homogeneous. No endocardial lesion is seen. The valve leaflets are thin and pliable, and no valvular abnormalities are noted. The coronary arteries are patent and have no significant atherosclerosis. No lesion of the aorta or its major branches is noted.

Respiratory System

The right lung weighs 750 grams and the left lung, 700 grams. The lungs are dark red and exude fluid on pressure. There is reddening of the mucosa of the large bronchi, the trachea, the larynx and pharynx. Sooty material is noted along the surfaces. The airway is patent. The neck structures have no evidence of trauma.

Hemolymphatic System

The 80 gram spleen has a bluish wrinkled capsule and the dark red parenchyma is somewhat soft. No enlarged lymph nodes are found. The thymus has atrophic changes consistent with age.

Digestive System

No abnormality of the esophagus is noted. The stomach contains about 100 ml of partly digested, unidentified food and liquid. No residuals of medication are seen. The mucosa is intact and pink. No lesion of the small and large intestine is noted. The appendix is absent.

Hepatobiliary System

The 1100 gram liver has a smooth capsular surface and is of usual configuration. The usual lobular architecture is noted and the reddish-brown parenchyma has no fibrosis. The gallbladder and the extrahepatic bile ducts have the usual configuration and no lesion is noted.

Urogenital System

Each kidney weighs 155 grams. The capsules strip readily from smooth grey-brown cortical surfaces. No lesion of the parenchyma is noted. The calices, pelves, ureters and urinary bladder have no lesion. The uterus is not enlarged.

JANE DOE NO. 5, aka PATRICIA SOLTYSIK

No lesion of the endometrium or myometrium is noted. There are erosions around the external cervical os. The vaginal mucosa is somewhat reddened. No lesion is apparent. The tubes and ovaries are of usual configuration and no lesion is seen.

Endocrine System

The adrenals and thyroid are of usual size, color and consistency. The pituitary and parathyroids are not dissected. No lesion of the pancreas is noted.

Head and Central Nervous System

On reflection of the charred scalp, no hemorrhage is noted. The skull cap is removed in the usual fashion and after stripping the dura no skull fractures are found. The sectioned brain is sent to the Forensic Neuropathologist for further study.

GENERAL MICROSCOPIC DESCRIPTION

Heart (Slides No. 8-2,4)

The myocardial fibers are uniform and appear unremarkable. The junction of atrial septum and ventricular septum is noted with some conduction fibers included. These are unremarkable. The bases of the valves are intact. There is some engorgement of the vascular bed of the heart. There is a small endocardial fibrous plaque in the left ventricular side of the septum. There is minimal perivascular fibrosis around some of the coronary artery tributaries. One small arterial tributary has artifactual separation of the intima and media by apparent heat effect.

Lungs (Slide No. 8-3)

The lung parenchyma has intense congestion of the capillary bed and congestion of the larger vascular branches. There is extensive precipitation of proteinaceous material within alveolar spaces. There are patchy nonspecific aggregates of lymphocytes in the interstitium around occasional small vessels. There is sparse anthracotic pigment. No granulomas are seen.

Spleen (Slide No. 8-6)

The spleen has prominent white pulp follicles. Splenic parenchyma does not have significant vascular congestion and the capsule is wrinkled. The trabeculation is normal.

JANE DOE NO. 5, aka PATRICIA SOLTYSIK

Liver (Slide No. 8-6)

The liver has well-preserved architecture with normal hepatocytes. Portal triads have no significant inflammatory infiltrate. There is no fatty change or cholestasis.

Pancreas (Slide No. 8-1)

Pancreatic tissue has early autolytic change, but the architecture is essentially preserved. Islets of Langerhans are unremarkable.

Intestine (Slides 7-3,4,6)

All sections of intestinal tissue have marked autolysis of the epithelial structures.

Kidneys (Slides No. 8-1,4)

There is some postmortem autolytic change of the proximal tubules. There is engorgement of the capillary bed, glomeruli and interstitium, but no structural alterations are observed.

Adrenal (Slide No. 8-7)

The adrenal has a normal cortex which is lipid poor. There is capillary congestion of the inner cortex and medulla. Medullary elements are unremarkable.

Uterus Slide No. 8-5)

There is residual, partially-autolyzed, endometrium which appears non-phasic. The myometrium is within normal limits.

Rectum and Vagina (Slide No. 7-2)

Rectal mucosa has early autolysis and prominent lymphoid patches, but is otherwise unremarkable. The vaginal side of the specimen has the normal rugal epithelium with moderate vascular congestion.

Urethra (Slide No. 7-1)

The urethra has intense subacute and chronic inflammation with lymphoid nodules surrounding the urethral epithelium. The adjacent vulvar tissue is unremarkable.

Ovaries (Slide No. 8-7)

The ovary has numerous cystic follicles with some thecal

JANE DOE NO. 5, aka PATRICIA SOLTYSIK

luteinization and mild thickening of the ovarian tunica albuginea.

FORENSIC NEUROPATHOLOGY EXAMINATION

Gross Findings

The brain has been previously cut coronally into five sections through the following levels: striatum; mammillary bodies; just behind the midbrain; the preoccipital notches.

The leptomeninges are thin and transparent. There is no blood or blood pigment either on the external surface or in the subarachnoid space. The cerebral convolutions are flattened throughout. There is no subfalcial herniation. The uncinata gyri and the parahippocampal gyri cannot be evaluated due to previous sectioning of these structures. The brain stem has been previously removed from the cerebrum. The superficial blood vessels of the cerebrum have some focal areas of congestion, but for the most part they have been emptied of their contents. There is no evidence of pathologic defect on the remaining recognizable portions of the external surfaces of the cerebrum. The specimen has a pinkish discoloration in some areas, but it appears to be fairly well fixed by formalin.

The cerebrum is further sectioned at 0.5 to 1 cm intervals revealing normal appearing cerebral cortex and white matter. The ventricles and sulci are markedly narrowed. The cut surfaces are mostly pale pink without hemorrhage, necrosis or foreign body. The basal ganglia and thalami are well preserved. The hippocampi are only partially preserved and have no abnormalities.

The brain stem has also been previously sectioned revealing no abnormalities on the cut surfaces. Further sections at 2 to 3 mm intervals have no lesions.

The cerebellum has been previously sectioned horizontally revealing no lesion, and further sections also show no lesion. There is a large herniation of the cerebellar tonsils which, however, are not necrotic or hemorrhagic.

Sections through the midbrain have congestion of the larger blood vessels.

The entire spinal cord with dura is included. There is no hemorrhage on the epidural or subdural surfaces. The

JANE DOE NO. 5, aka PATRICIA SOLTYSIK

leptomeninges are thin and transparent. The size, configuration and consistency of the cord are within normal limits. The specimen also includes a 5 cm segment of the cauda equina. The total length of the spinal cord is 38 cm down to the conus. Transverse sections at less than 1 cm intervals of the entire cord have some loss of normal configuration in the mid-cervical regions where there is actually a whitish core about 3 to 4 mm in size. The remainder of the transverse sections show no abnormalities. There is no hemorrhage.

Microscopic Description

All sections have congestion and extravasation with hemolysis of the intravascular blood. The endothelium is swollen. The cerebral cortex has acute swelling of the nerve cells where the nuclei take on a rather faint stain, but the nucleoli are fairly distinct. The cytoplasm has a varying degree of homogenization with disappearance of the Nissl bodies. The glial cells, both in the cortex and white matter, have uniform swelling and the matrices are homogenized. The basal ganglia have similar changes of the nerve cells, but to a much lesser extent.

In the midbrain, the pigmented cells of the substantia nigra have a normal amount of pigment but their color is rather light. Acute swelling of the nuclei is present.

The pontine nuclei and fibers are well-preserved. In the medulla, the nerve cells of the olives have quite extensive central chromatolysis. The fiber tracts are swollen and granular.

The spinal cord has varying degrees of changes of the anterior horn cells, but most of them are quite well preserved. Some are poorly stained and a few have central chromatolysis. The fiber tracts are swollen and granular.

The cerebellum has fairly good preservation of the granular cells, but the Purkinje cells are markedly swollen and most of them have varying degrees of homogenization. The nuclei are rather indistinct, although the nucleoli are still visible. The glial cells have swollen nuclei.

Diagnoses

1. Essentially normal brain and spinal cord with postmortem heat-induced changes.

JANE DOE NO. 5, aka PATRICIA SOLTYSIK

FORENSIC RADIOLOGY EXAMINATION

Skull

A single AP view of the skull has no evidence of fracture. Several tiny metallic densities are noted in this projection.

Thorax

No rib fractures or other bony trauma are identified. An irregular dense metallic fragment is noted overlying the posterolateral aspect of the right 5th rib. The fragment measures 1/2 inch (1.3 cm) in greatest dimension in the projection of the film. There are tiny satellite densities. A dense metallic fragment is also noted over the posterolateral aspect of the right 8th rib. This fragment measures 3/8 inch (1.0 cm) in diameter in the projection of the film.

Abdomen and Pelvis

There is no evidence of bony trauma. There are two irregular thin metallic densities measuring up to 3/8 inch (1.0 cm) in greatest dimension, which appear to lie along the lateral aspect of the mid and upper abdomen on the right side. There are scattered fine metallic densities overlying the inferior ischiopubic junction on the right.

Extremities

No fractures or other bony trauma are seen. Projected over the upper right femur and adjacent soft tissue, there are two ammunition primers and a primer anvil. Projected over the lower portion of the right femur and adjacent soft tissue, there are two irregular metallic densities measuring respectively 3/8 inch (1.0 cm) and 7/8 inch (4.7 cm) in greatest dimension.

Along the mid shaft of the right humerus there is an ammunition primer, a primer anvil and an intact bullet measuring, in the projection of the film, nearly 3/4 inch (1.9 cm) in length, and about 3/8 inch (1.0 cm) in diameter, and a 7/8 x 3/8 inch (2.2 x 1.0 cm) exploded cartridge case. Partially overlying the neck of the exploded cartridge case is an irregular thin metallic density measuring 3/4 x 1/2 inch (1.9 x 1.3 cm). In surrounding areas there are scattered fine metallic densities. Scattered fine metallic densities are noted in the left axillary region and over the hands.

In the area of the left olecranon, there is partly deformed bullet measuring about 3/4 x 1/2 inch (1.9 x 1.3 cm) in

JANE DOE NO. 5, aka PATRICIA SOLTYSIK

greatest dimension. Adjacent to the bullet, there is a partly cylindrical thin metallic density measuring about 3/4 x 1/2 inch (1.9 x 1.3 cm) in greatest dimension. An incidental small exostosis of the distal portion of the left humerus is noted.

FORENSIC ODONTOLOGY EXAMINATION

The maxilla and mandible of Jane Doe No. 5, Case No. 74-6765, are examined. Arch form is generally good and numerous restorations are noted. The posterior teeth are filled with amalgam.

The maxilla, mandible, and postmortem radiographs are compared to the antemortem radiographs and a dental chart labelled "Pat Soltysik". The postmortem radiographs, dated 5-18-74, consist of two lateral jaw films, fourteen periapical films, and four bite-wing films. The antemortem radiographs consist of four bite-wings of 8-24-72, two bite-wings of 3-15-72, and two bite-wings of 9-15-71. The most recent entry on the dental chart is 5-25-73, and the earliest entry is 7-25-67.

There are virtually an infinite number of matching points when the antemortem and postmortem evidence is compared. In both sets of records, all posterior teeth are present, except for Teeth No. 17 and No. 32. All fillings visualized in the antemortem radiographs are present in the postmortem material. A number of distinctive fillings are visualized in the antemortem radiographs and matched in the postmortem radiographs, including fillings in Teeth No. 2, No. 3, No. 4, No. 13, No. 15, No. 18, No. 20 and No. 28.

Conclusion

There is a positive match between the jaws and postmortem radiographs of Jane Doe No. 5, Case No. 74-6765, and the dental radiographs and chart labelled "Pat Soltysik."

FORENSIC TOXICOLOGY EXAMINATION

| <u>Specimen</u> | <u>Compound</u> | <u>Result</u> |
|-----------------|---|---------------|
| <u>Blood</u> | Amphetamines | Neg. |
| | Carbon monoxide (CO) saturation | 25.5% |
| | Ethanol, Barbiturates and Neutral Drugs | Neg. |

JANE DOE NO. 5, aka PATRICIA SOLTYSIK

| <u>Specimen</u> | <u>Compound</u> | <u>Result</u> |
|-----------------|---|---------------|
| <u>Blood</u> | Morphine, Codeine and Cocaine | Neg. |
| | Salicylates, Trichlorethanol, Ethchlorvynol, Basic Drugs, Diphenhydramine, and Oxazepam | Neg. |
| | "Tear Gas" (i.e., Chloroacetophenone (CN) and O-chlorobenzalmalononitrile (CS) | Neg. |
| | Gasoline | Neg. |
| | Cyanide determination | Neg. |
| <u>Liver</u> | Barbiturates and Neutral Drugs | Neg. |
| | Phenothiazines and Basic Drugs | Neg. |
| <u>Lung</u> | "Tear Gas" (i.e., Chloroacetophenone (CN) and O-chlorobenzalmalononitrile (CS) | Neg. |
| <u>Bile</u> | Morphine, Codeine and Cocaine | Neg. |

FORENSIC BIOLOGY EXAMINATION

Material Submitted

Blood for Typing

Findings

Type: O
Rh: Negative

Material Submitted

Vaginal and Anal Smears

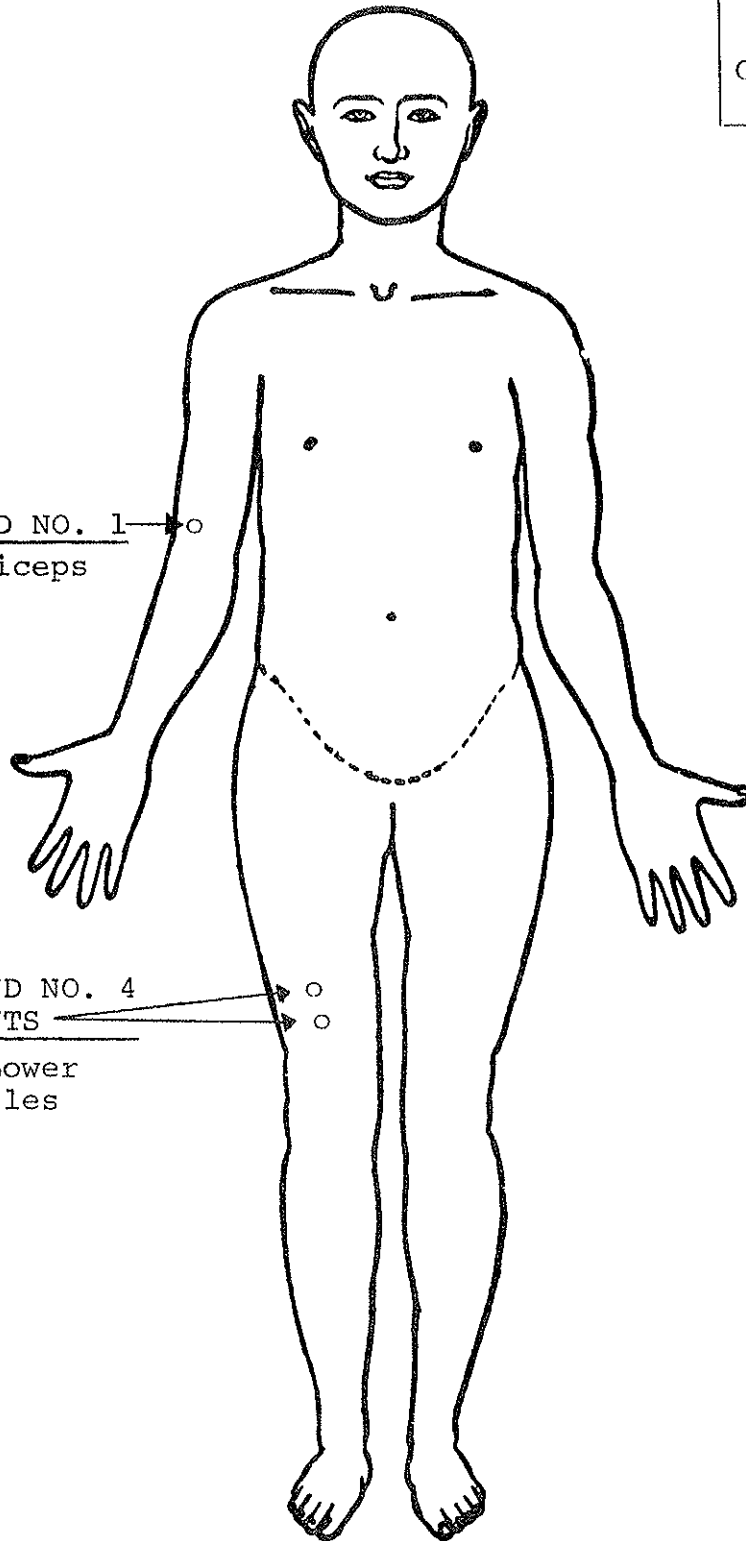
Findings

Acid phosphatase - no reaction
No sperm seen

20
A

JANE DOE NO. 5,
aka PATRICIA SOLTYSIK

Case No. 74-6765



GUNSHOT WOUND NO. 1 → ○
In Right Biceps
Muscle

R

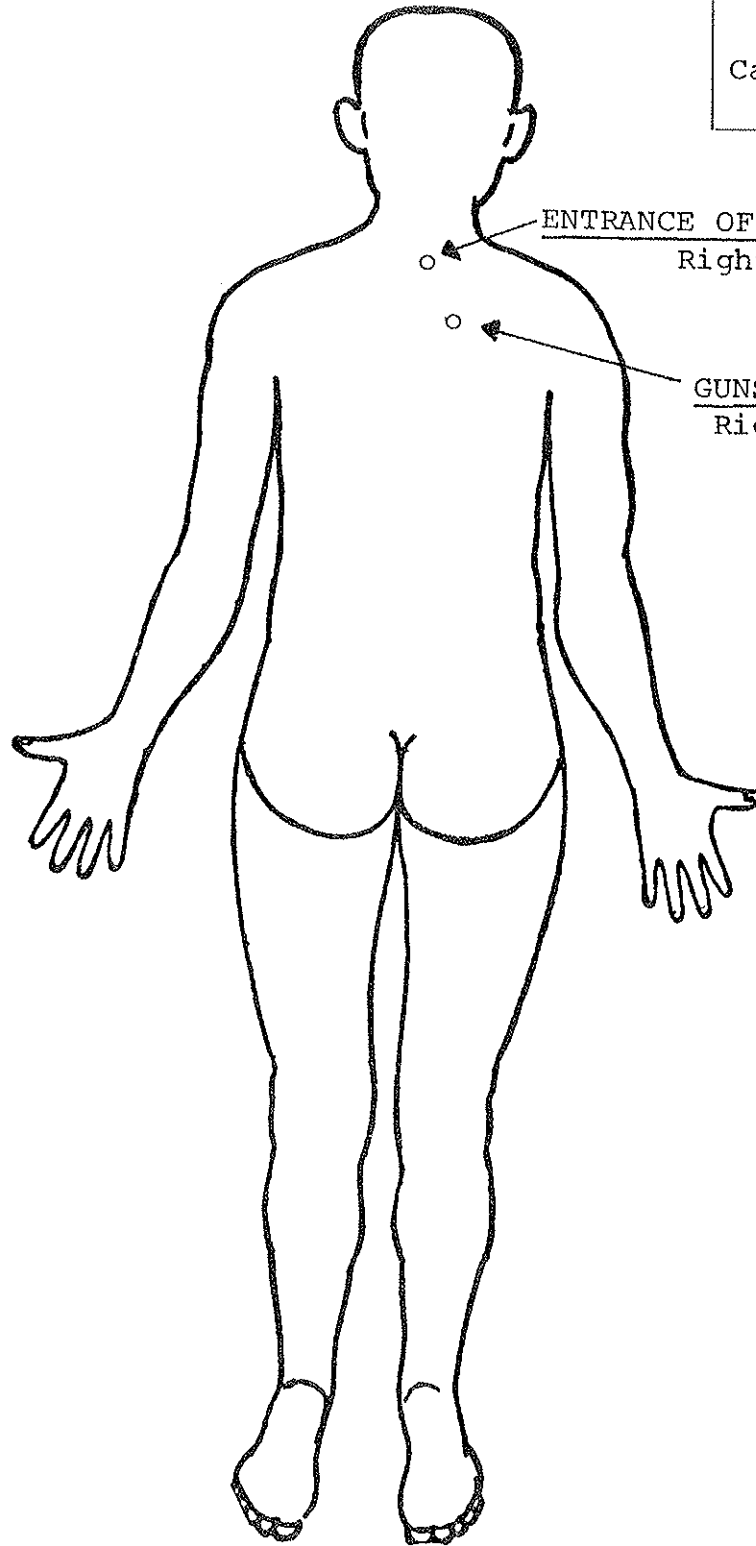
L

GUNSHOT WOUND NO. 4
FRAGMENTS → ○
→ ○
In Right Lower
Thigh Muscles

Deputy Medical Examiner. M.D.

20 B

JANE DOE NO. 5,
aka PATRICIA SOLTYSIK
Case No. 74-6765



ENTRANCE OF GUNSHOT WOUND NO. 2
Right Upper Back

ENTRANCE OF GUNSHOT WOUND NO. 3
Right Upper Back

L

R

Deputy Medical Examiner M.D.

COUNTY OF LOS ANGELES
DEPARTMENT OF CHIEF MEDICAL EXAMINER-CORONER

NAME JANE DOE NO. 5, aka PATRICIA SOLTYSIK Date May 18, 1974 File No. 74-6765

| | UPPER RIGHT | | | | | | | | | | UPPER LEFT | | | | | |
|--------------------------|-------------------------------------|----|----|----|--------|---|---|---|---|----|--|--------|----|----|----|---------------------------------|
| | 1 | 2 | 3 | 4 | 5 | 6 | 7 | 8 | 9 | 10 | 11 | 12 | 13 | 14 | 15 | 16 |
| Rotated mesial to buccal | | | | | | | | | | | | | | | | |
| | A. | A. | A. | A. | Normal |) |) |) |) |) | Normal | Normal | A. | A. | A. | Normal except for darkish color |
| | MO and DO filled separately | | | | | | | | | | Nos. 7 through 10 are normal, well aligned but slightly spaced | | | | | |
| | DOL is more recent filling | | | | | | | | | | | | | | | |
| | Not clinically evident | | | | | | | | | | Not clinically evident | | | | | |
| | Mesial white restorations | | | | | | | | | | Carries on D | | | | | |
| | Plastic, very hard, possibly enamel | | | | | | | | | | | | | | | |

| | LOWER RIGHT | | | | | | | | | | LOWER LEFT | | | | | |
|------------------------|------------------------|----|--------|----|--------|----|----|----|----|----|------------------------|----|----|----|----|----|
| | 32 | 31 | 30 | 29 | 28 | 27 | 26 | 25 | 24 | 23 | 22 | 21 | 20 | 19 | 18 | 17 |
| Not clinically evident | | | | | | | | | | | | | | | | |
| | A. | A. | Normal | A. | Normal | (| (| (| (| (| Normal | A. | A. | A. | | |
| | Not clinically evident | | | | | | | | | | Not clinically evident | | | | | |

LEGEND:

Amalgam: A; Gold: G; Silicate: S;
Acrylic: Ac; Missing Teeth: X

JANE DOE NO. 5, aka PATRICIA SOLTYSIK

REPORT OF AT-SCENE AND FOLLOW-UP INVESTIGATION

Doe No. 5, later identified as Jane Doe No. 5, aka Patricia Soltysik, was found in a kneeling position, partially lying across Doe No. 4, just to the east of Doe No. 4, inside the southeast corner of the burned structure. The head was facing to the south near the air vent. The body was extensively charred.

The decedent was brought to the Forensic Science Center at 2305 hours on May 17, 1974 by the Coroner's Senior Investigator and Investigator.

Physical Description

Female Caucasian; 21 plus years of age; charred
Height: 63 inches
Weight: 123 pounds

Clothing on Body

The articles of burned clothing were inventoried and released to the Scientific Investigation Division of the Los Angeles Police Department on May 18, 1974 at 1610 hours.

Personal Property Found on Body

The articles of personal property were inventoried and released to the Scientific Investigation Division of the Los Angeles Police Department on May 18, 1974 at 1600 hours, with the exception of \$320.00 in currency, which is retained in the Coroner's custody until completion of the investigation.

Additional Evidence Found on Body

Additional evidence was found on the body by the Coroner's Medical Photographer on May 18, 1974, between the hours of 0310 and 0345, while photographing the body at the Forensic Science Center. The evidence was inventoried and later released to the Scientific Investigation Division of the Los Angeles Police Department on May 20, 1974 at 1430 hours.

COUNTY OF LOS ANGELES
DEPARTMENT OF CHIEF MEDICAL EXAMINER-CORONER
LOS ANGELES, CALIFORNIA 90033

JANE DOE NO. 6, aka CAMILLA HALL

Case No. 74-6828

This is to certify that the autopsy on the body of Camilla Hall was performed at The Forensic Science Center, Los Angeles, by the staff of the Department of Chief Medical Examiner-Coroner, on May 19, 1974.

CAUSE OF DEATH: GUNSHOT WOUND TO HEAD

The detailed medical findings, opinions and conclusions required by Section 27491 of the Government Code of California are attached.

Thomas T. Noguchi, M.D.
Chief Medical Examiner-Coroner

ANATOMICAL SUMMARY

GUNSHOT WOUNDS

1. Gunshot wound through head, fatal.
2. Gunshot wound left upper arm, non-fatal.

OTHER FINDINGS

1. Leiomyoma of uterus, small.
2. Subacute cervicitis, moderate.

POSTMORTEM CHANGES

1. Postmortem burns of skin, subcutaneous tissue, muscle and bone, extensive.
2. Postmortem decomposition, moderate.

SUMMARY OF GUNSHOT WOUNDS

Gunshot Wound No. 1, Head, Fatal

Entry: Right frontal region.

Direction: Anterior to posterior; no further characterization possible.

Course: Not determinable (massive avulsion of skull and brain).

Exit: Not determinable.

Projectile Recovery and Identification: Small metallic fragments found around entry.

Gunshot Wound No. 2, Left Upper Arm, Non-Fatal

Entry: Not determinable (skin and subcutaneous tissues of arm burned away).

Direction: Superior to inferior; no further characterization possible.

Course: Short, hemorrhagic track within left biceps muscle.

Exit: None.

Projectile Recovery and Identification: .223 caliber copper-jacketed bullet.

JANE DOE NO. 6, aka CAMILLA HALL

DESCRIPTION OF GUNSHOT WOUNDS

Gunshot Wound No. 1, Head, Fatal

No entrance wound of the scalp or skull can be determined because of avulsion of scalp and skull and subsequent charring. A 3/4 x 1/4 inch (1.0 x 0.6 cm) entrance wound in the dura mater can, on reconstruction, be placed 1 inch (2.5 cm) to the right of the midline of the forehead, and 1 inch (2.5 cm) inferior to the top of the head. No powder residue is found around this entrance wound. Four satellite wounds, each measuring about 1/8 inch (0.3 cm) in diameter, are located radially up to 1/8 inch (0.3 cm) away from the main entrance wound in the dura. There has been massive disruption and avulsion of skull and brain tissue, so that no direction of the bullet through the cranial contents can be ascertained. Principal portions of the superior and posterior calvarium are missing. There are comminuted fractures of the frontal portions of the skull extending downward towards the base. There are fractures along the base, particularly of the sphenoid, temporal bones and orbital plates. The brain has been almost completely avulsed and is missing. A small portion of pons remains along the base of the skull. No exit wound can be identified because of massive avulsion of the posterior aspect of the skull with subsequent charring. The dura along the posterior aspect is missing.

Gunshot Wound No. 2, Left Upper Arm, Non-Fatal

No entry wound can be determined because of charring away of skin and subcutaneous tissues of the left arm. The track is found within the biceps muscle, extending from above downward. The margins of the track are hemorrhagic and at the end of the track a partly-deformed, fired, copper-jacketed bullet is found (later identified as a .223 caliber bullet).

Note

The melted lead fragment removed from exposed surface of left pectoral muscle is not concluded to represent a missile. There is no associated wound track.

MICROSCOPIC DESCRIPTION OF GUNSHOT WOUNDS

Gunshot Wound No. 1, Head, Fatal

The entrance wound in the dura has coagulated blood cells and fibrin along one surface, and an area of disruption and separation of fibers along one edge. There appears to be carbonaceous material adherent to the surface and within

JANE DOE NO. 6, aka CAMILLA HALL

tissue of the disrupted fragmented edge. No powder residue is identified.

Gunshot Wound No. 2, Left Upper Arm, Non-Fatal

No microscopic study (no identifiable entry wound).

GENERAL EXTERNAL DESCRIPTION

The unembalmed body is that of a well-developed and apparently well-nourished white female of 20 to 30 years of age, weighing 90 pounds (40.9 kg), and measuring 66 inches (168 cm) in length in the present condition. There is an odor of early decomposition. No identifying marks, scars, or tattoos are found on the body. There is extensive skin loss due to heat, with charring of exposed subcutaneous fat and muscles. Intestines protrude through a gaping, charred hole in the abdomen. The skin of the left hand has been charred away, as has most of the skin of both legs. There is charring of the right hand, which has a small amount of palmar skin present. Lateral aspects of the back have extensive skin loss, as have the buttocks. Remaining skin is dark brown and indurated, except for some sparing of the skin along the right flank and the lateral aspect of the right chest wall. No vital reaction to any heat-induced changes of the skin or underlying tissues is identified. The perianal skin and external genitalia have extensive heat changes. No distinct lesion is apparent. The anal opening is not dilated and no foreign bodies are seen.

Primary Incision

The body is opened with the usual Y-shaped incision.

Body Cavities

The pleural, pericardial and peritoneal cavities are lined by smooth, glistening membranes and there are physiologic amounts of fluid within these spaces.

Cardiovascular System

The heart weighs 250 grams and is of usual configuration. There is no dilatation of the chambers or hypertrophy of the muscular walls. The myocardium is reddish-brown, firm and homogeneous. No focal lesions are seen. The endocardial surfaces are smooth and glistening. The coronary arteries have no significant atherosclerosis. No dilatation or other lesion of the aorta is seen.

JANE DOE NO. 6, aka CAMILLA HALL

Respiratory System

The right lung weighs 700 grams and the left lung, 650 grams. There is reddish basilar congestion of both lungs. There is no consolidation. The mucosa of the tracheobronchial tree is pink and no sooty material is found. The neck structures have no evidence of trauma. The airway is patent, and no inflammation of the laryngeal mucosa is found.

Hemolymphatic System

No blood is present in principal vessels. The 80 gram spleen is of usual configuration. The cut surfaces are reddish-blue and somewhat soft. No enlarged lymph nodes are found. The thymus is atrophic, consistent with age.

Digestive System

The esophagus is of usual size and configuration. No inflammation of the mucosa is seen. The stomach contains about 50 ml of partly digested, unidentified food material. No residuals of medication are found, and no inflammation of the mucosa is seen. No external or internal lesion of the small and large intestines is noted. The appendix is present.

Hepatobiliary System

The 1050 gram liver has smooth external surfaces and sharp edges. The reddish-brown parenchyma has the usual lobular pattern with no fibrosis. The gallbladder and extrahepatic ducts appear normal.

Urogenital System

The kidneys are of usual configuration and each weighs 150 grams. The capsules strip readily from smooth grey-brown cortical surfaces. On sectioning, no focal lesions are found. The pelves, ureters and urinary bladder have no abnormal findings. The uterus is of average size. Around the external cervical os there are small reddish erosions. An intramural 0.6 cm, whorled fibrous nodule presents along the anterior surface of the midportion of the uterus. The endometrium is of medium thickness. No intrauterine foreign bodies are found. No abnormalities of the ovaries and fallopian tubes are found.

Endocrine System

The adrenal and thyroid glands are of usual size, color and consistency as is the pancreas.

JANE DOE NO. 6, aka CAMILLA HALL

Central Nervous System

All that remains of the brain is a portion of pons within which no preexisting lesion is identified. The spinal cord is sent to the Forensic Neuropathologist for study.

GENERAL MICROSCOPIC DESCRIPTION

Heart (Slides No. 11-7,10)

The myocardium is markedly autolyzed. No lesion is identified. Branches of coronary arteries are essentially well *preserved*.

Trachea (Slide No. 11-10)

There is marked autolysis with sloughing of the epithelium and sub-epithelial tissues. The cartilage has variable staining and some fragmentation.

Epiglottis (Slide No. 11-6)

A portion of the stratified squamous epithelium is preserved. The epiglottic cartilage is unremarkable. On another edge of the epiglottis, there is complete denudation of the surface epithelium and a small amount of carbonaceous material is adherent.

Spleen (Slide No. 11-9)

The spleen has marked autolysis with only cellular outlines remaining. The trabeculae are visible.

Liver (Slide No. 11-7)

There is marked autolysis with only ghost-like outlines of liver cells. Scattered bacterial colonies are seen. The general architecture and lobular pattern is of usual configuration.

Appendix (Slide No. 11-6)

There is extensive autolysis. No lesion is identified.

Kidney (Slide No. 11-5)

There is almost total autolysis of all cellular elements.

Uterus (Slide No. 11-4)

The endometrium is mostly autolyzed, but some residual

JANE DOE NO. 6, aka CAMILLA HALL

glands are seen. There is no evidence of gestational material within the uterus. There is a circumscribed leiomyoma within the myometrium.

Ovary (Slide No. 11-6)

The ovary has marked autolysis and heat-coagulation change. A small cystic follicle is noted.

Vulva (Slides No. 11-1,11)

There is extensive heat-induced change of the vulvar skin. Residual sebaceous glands are noted. There is carbonaceous material and debris embedded in the tissue. There is port-mortem bacterial growth.

Thyroid Gland (Slide No. 11-5)

There is variation in follicle size, but no significant nodularity is noted. There is no inflammation.

FORENSIC NEUROPATHOLOGY EXAMINATION

Gross Findings

Specimen consists of the spinal cord which measures 39 cm down to the tip of the conus. The upper end appears to contain all the cervical segments. There is dura surrounding the lower 12 cm segment of the specimen. There is a small amount of areolar tissue and some adipose tissue on the epidural surfaces, but there is no blood. The subdural surface is grayish, smooth and glistening without blood or neomembrane. The entire dura has a light gray discoloration. The dura fits the spinal cord quite snugly.

The leptomeninges are gray in color, especially the cervical and thoracic portions. They are thin and slightly opaque. The spinal cord retains the usual configuration. Its consistency is fairly firm in the cervical region. In the thoracic region, it is markedly softened. In the mid-thoracic portion, where the dorsal portion has been removed, the cord is actually mushy and has a whitish or light buff color. The lower thoracic and lumbosacral regions are much firmer and similar to that of the cervical region. There is no subarachnoid hemorrhage. There are a few short nerve roots in the cervical region. These are grossly intact. No posterior root ganglia are included. In the remainder of the cord, there are only occasional nerve roots remaining attached.

JANE DOE NO. 6, aka CAMILLA HALL

Multiple transverse sections of the spinal cord have a mottled appearance. The distinction between the gray and white matter is very much obscured. The more softened portions in the thoracic regions have a homogeneous appearance without recognizable anatomic features.

Microscopic Examination

Sections from the cervical, lower thoracic and lumbar regions have very poor staining of the anterior horn cells. The nuclei and Nissl bodies stain red, as does the cytoplasm. The glial cells have poor to fair staining of their nuclei. The myelin sheath is coarsely granular or even nodular. The axons are uniformly swollen. Sections from the upper thoracic region, grossly mushy, have no nuclear staining at all. All structures stain red and are granular. The structural outline is somewhat preserved. The meninges stain red. The blood vessels have swollen endothelia and walls.

Diagnoses

1. Essentially normal spinal cord with heat-induced and decompositional changes.

FORENSIC RADIOLOGY EXAMINATION

In all views examined, there are very fine and somewhat larger metallic fragments along surfaces and projected over soft tissues. In places, somewhat larger fragments can be identified as metallic ammunition primers and primer anvils. Scattered, thin, irregular, metallic pieces are consistent with shell case fragments.

Thoraco-Abdominal Area

There is considerable postmortem soft tissue gas formation with dissection along tissue planes. There is no evidence of bony trauma.

Skull

A single AP projection of the skull, following disarticulation of the mandible, has a "blow-out" injury of the entire calvarium, with two major remaining bony fragments. There does not appear to be any involvement of the petrous pyramids. Multiple tiny metallic densities, round and irregular, are projected over all areas.

JANE DOE NO. 6, aka CAMILLA HALL

Right Frontal Dura (Specimen View)

Several fine metallic densities are noted adjacent to a central defect.

Extremities and Pelvis

No bony trauma is demonstrated. Geographic fractures of the distal ends of the right tibia and fibula are consistent with heat fractures. Similar fractures of the distal end of the left humerus and the proximal end of the left ulna are noted. Overlying the outer aspect of the left humerus and adjacent soft tissues, there is an irregular 7/8 x 3/8 inch (2.2 x 1.0 cm) dense metallic object with one pointed end. At about the same level, either overlying or within soft tissues of the inner aspect of the left upper arm, there is an irregular, thin fragment of metallic material measuring 3/4 x 3/4 inch (1.9 x 1.9 cm) in the projection of the film. No injury to the humerus at this level is found.

FORENSIC ODONTOLOGY EXAMINATION

The maxilla and mandible of Jane Doe No. 6, Case No. 74-6828, are examined. The decedent appears to have received orthodontic treatment, with removal of maxillary and mandibular first bicuspids. Arch form is good, and occlusion is consistent with a satisfactorily completed four bicuspid orthodontic extraction case. Amalgam fillings are present in all posterior teeth and the third molars are absent.

The maxilla, mandible and postmortem radiographs are compared to bite-wing radiographs labelled "Camille Hall", and written information describing dental treatment for "Camilla Hall." The postmortem radiographs are dated 5-19-74 and consist of fourteen periapical films and four bite-wing films. The antemortem radiographs consist of four bite-wing films dated 9-7-72. The written information consists of a patient information card and a slip of paper dated 9-7-72, listing five amalgam restorations. The paper and card are contained in an envelope labelled "Camilla Hall's Dental Records."

All five fillings referred to above are visualized in the teeth of Jane Doe No. 6. All restorations visualized in the antemortem radiographs are present or accounted for in the teeth of Jane Doe No. 6. There are almost an infinite number of matching points when the antemortem and postmortem radiographs are compared. Many of the matching restorations are highly characteristic in contour, including fillings in Teeth No. 3, No. 29, No. 30 and No. 31. Teeth and contours of distinctive fillings match well when the two sets of radiographs are superimposed.

JANE DOE NO. 6, aka CAMILLA HALL

Conclusion

The jaws and postmortem radiographs of Jane Doe No. 6, Case No. 74-6828, are a positive match with the radiographs and dental records labelled "Camile Hall" and "Camilla Hall."

FORENSIC TOXICOLOGY EXAMINATION

| <u>Specimen</u> | <u>Compound</u> | <u>Results</u> |
|-----------------|---|----------------|
| <u>Liver</u> | Morphine, Codeine and Cocaine | Neg. |
| | Barbiturates and Neutral Drugs | Neg. |
| | Basic Drugs | Neg. |
| | Gasoline | Neg. |
| <u>Lung</u> | "Tear Gas" (i.e., Chloroacetophenone (CN) and O-chlorobenzalmalonitrile (CS) | Neg. |
| <u>Bile</u> | Morphine, Codeine and Cocaine | Neg. |
| <u>Kidney</u> | Amphetamines | Neg. |
| <u>Spleen</u> | Trichlorethanol and Ethchlorvynol | Neg. |

20
A

GUNSHOT WOUND NO. 1
Avulsion of Scalp,
Skull and Brain

JANE DOE NO. 6, aka
CAMILLA HALL

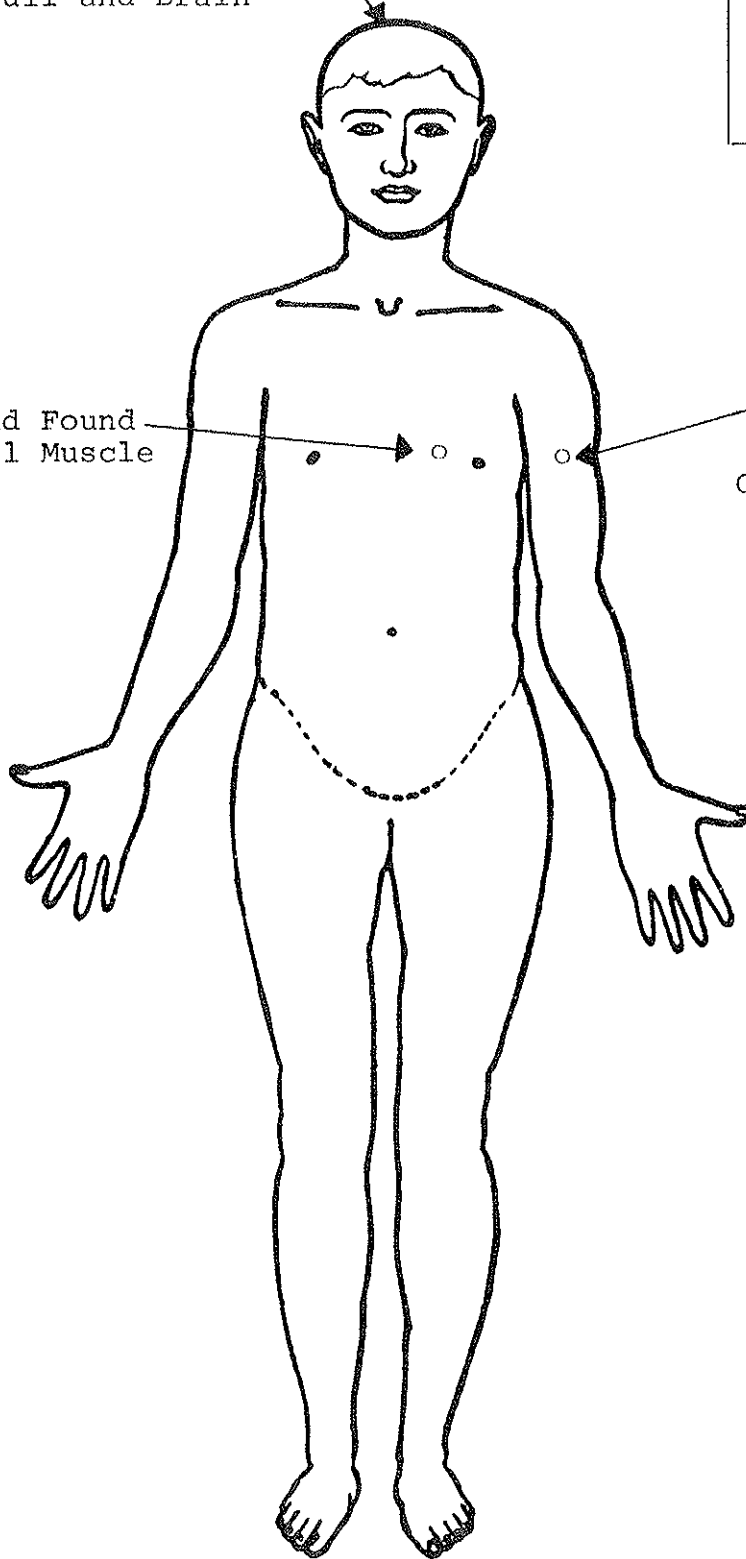
CASE NO. 74-6828

Melted Lead Found
in Pectoral Muscle

GUNSHOT WOUND NO. 2
Bullet Found in
Charred Biceps Muscle
(.223 caliber)

R

L



COUNTY OF LOS ANGELES
DEPARTMENT OF CHIEF MEDICAL EXAMINER-CORONER

NAME JANE DOE NO. 6, aka CAMILLA HALL Date May 19, 1974 File No. 74-6828

| UPPER RIGHT | | | | | | | | | | | | | | | | UPPER LEFT | | | | | | | | | | | | | | | |
|---|----|----|----|----|----|----|----|----|----|----|----|----|----|----|----|---|----|----|----|----|----|----|----|----|----|----|----|----|----|----|----|
| 1 | 2 | 3 | 4 | 5 | 6 | 7 | 8 | 9 | 10 | 11 | 12 | 13 | 14 | 15 | 16 | 16 | 15 | 14 | 13 | 12 | 11 | 10 | 9 | 8 | 7 | 6 | 5 | 4 | 3 | 2 | 1 |
| Missing | | | | | | | | | | | | | | | | Missing | | | | | | | | | | | | | | | |
| A. | | | | | | | | | | | | | | | | A. | | | | | | | | | | | | | | | |
| A. | | | | | | | | | | | | | | | | A. | | | | | | | | | | | | | | | |
| A. Appears relatively re-cent compared to others Missing--space completely closed | | | | | | | | | | | | | | | | A. Appears relatively re-cent compared to others Missing--space completely closed | | | | | | | | | | | | | | | |
| Normal; slightly charred | | | | | | | | | | | | | | | | Normal; slightly charred | | | | | | | | | | | | | | | |
| Present, but charred | | | | | | | | | | | | | | | | Present, but charred | | | | | | | | | | | | | | | |
| Normal; slightly charred | | | | | | | | | | | | | | | | Normal; slightly charred | | | | | | | | | | | | | | | |
| Normal | | | | | | | | | | | | | | | | Normal | | | | | | | | | | | | | | | |
| Missing--space completely closed | | | | | | | | | | | | | | | | Missing--space completely closed | | | | | | | | | | | | | | | |
| A. | | | | | | | | | | | | | | | | A. | | | | | | | | | | | | | | | |
| A. | | | | | | | | | | | | | | | | A. | | | | | | | | | | | | | | | |
| A. | | | | | | | | | | | | | | | | A. | | | | | | | | | | | | | | | |
| Missing | | | | | | | | | | | | | | | | Missing | | | | | | | | | | | | | | | |
| LOWER RIGHT | | | | | | | | | | | | | | | | LOWER LEFT | | | | | | | | | | | | | | | |
| 32 | 31 | 30 | 29 | 28 | 27 | 26 | 25 | 24 | 23 | 22 | 21 | 20 | 19 | 18 | 17 | 17 | 18 | 19 | 20 | 21 | 22 | 23 | 24 | 25 | 26 | 27 | 28 | 29 | 30 | 31 | 32 |
| Missing | | | | | | | | | | | | | | | | Missing | | | | | | | | | | | | | | | |
| A. | | | | | | | | | | | | | | | | A. | | | | | | | | | | | | | | | |
| A. | | | | | | | | | | | | | | | | A. | | | | | | | | | | | | | | | |
| A. | | | | | | | | | | | | | | | | A. | | | | | | | | | | | | | | | |
| Missing; approx. 1 mm. space remains | | | | | | | | | | | | | | | | Missing; approx. 1 mm. space remains | | | | | | | | | | | | | | | |
| Normal and extremely well aligned | | | | | | | | | | | | | | | | Normal and extremely well aligned | | | | | | | | | | | | | | | |
| Missing--space completely closed | | | | | | | | | | | | | | | | Missing--space completely closed | | | | | | | | | | | | | | | |
| A. | | | | | | | | | | | | | | | | A. | | | | | | | | | | | | | | | |
| A. | | | | | | | | | | | | | | | | A. | | | | | | | | | | | | | | | |
| A. | | | | | | | | | | | | | | | | A. | | | | | | | | | | | | | | | |
| Missing | | | | | | | | | | | | | | | | Missing | | | | | | | | | | | | | | | |

LEGEND:

Amalgam: A; Gold: G; Silicate: S;
Acrylic: Ac; Missing Teeth: X

JANE DOE NO. 6, aka CAMILLA HALL

REPORT OF AT-SCENE AND FOLLOW-UP INVESTIGATION

Doe No. 6, later identified as Jane Doe No. 6, aka Camilla Hall, was discovered on May 19, 1974 at 0905 hours, by the Criminal Conspiracy Division of the Los Angeles Police Department. The body was in a prone position, head facing south, approximately 18 inches east of Doe No. 2, inside the southwest corner of the burned structure. The body was extensively charred.

A packet of possibly undischarged but destroyed shotgun shells were found between the ground and the abdomen of the decedent; this evidence was taken by the Los Angeles Police Department at the scene.

The decedent was brought to the Forensic Science Center on May 19, 1974 at 1215 hours by the Coroner's Investigator.

Physical Description

Female Caucasian; 21 plus years of age; charred
Height: 66 inches
Weight: 90 pounds

Clothing on Body

The articles of burned clothing were inventoried and released to the Scientific Investigation Division of the Los Angeles Police Department on May 19, 1974 at 1440 hours.

Personal Property Found on Body

The articles of personal property, consisting of \$1.95 in currency and coin, knife, ring and compass, are retained in the Coroner's custody until completion of the investigation.

Additional Evidence Found on Body

Additional evidence was found on the body by the Coroner's Medical Photographer on May 19, 1974 at 1500 hours while photographing the body at the Forensic Science Center. The evidence was inventoried and later released to the Scientific Investigation Division of the Los Angeles Police Department on May 20, 1974 at 1430 hours.

